

MINISTRY OF EDUCATION AND SCIENCE  
OF THE RUSSIAN FEDERATION  
Federal State Budgetary Educational Institution of Higher Education  
"I. N. Ulianov Chuvash State University»

**N. S. FEDOROVA**  
**V. N. VIKTOROV**

**DENTAL ORTHOPEDIC REHABILITATION OF PATIENTS  
WITH PERIODONTAL DISEASES**

**Training and methodical manual**

**Cheboksary 2022**

UDC 616.314.089.23(075.8)  
BCU R668ya73

*Reviewers:*

Doctor of Medical Sciences, Associate Professor, Rector of the State Autonomous Institution of the Chuvash Republic of Supplementary Professional Education "Post-Graduate Doctors' Training Institute" under the Public Health Ministry of the Chuvash Republic

**R. S. Matveev;**

Candidate of Medical Sciences, Associate Professor, Head of Maxillofacial Surgery and Dentistry Department **V. V. Trubin**

**Fedorova N. S.**

**Viktorov V.N.**

Dental orthopedic rehabilitation of patients with periodontal diseases: educational and methodical manual / N. S. Fedorova, V. N. Viktorov. Cheboksary: Chuvash University Publishing, 2022. 209 p.

The training-methodological manual is intended for teaching students, residents, dentists and is devoted to one of the main sections in orthopedic dentistry – dental orthopedic rehabilitation of patients with periodontal diseases. The manual considers in detail the etiological factors leading to this pathology; it gives clinical manifestations, current classifications as well as it describes in detail the principles of complex treatment for periodontal diseases, the information is illustrated by current schemes. The final section of the training manual presents clinical recommendations (treatment protocols) for the diagnosis of periodontitis, approved by the Decision of the Council of the of public entities association "Russian Dental Association" on April 23, 2013, as amended and supplemented on the basis of Resolution №15 of the Council of public entities association "Russian Dental Association" dated September 30, 2014.

Responsible editor doctor of medical sciences, professor  
Yu.N. Urukov

Approved by the Educational and Methodological Council of the University

UDC 616.314.089.23(075.8)  
BCU R668ya73

©Chuvash University Publ., 2022

©Fedorova N. S., Viktorov V.N. 2022

## ***PREFACE***

---

Parodontal diseases are one of the urgent problems in modern medicine. The symptoms of parodontitis cause daily discomfort of greater or lesser severity in a significant number of patients. This disease does not have age, racial or gender preference. According to the World Health Organization, the first signs of parodontal diseases are first detected at the age of 15-19 years (55-99%), in the age group of 35 years and older, from 65 to 98% of the population suffer from the disease.

In young people under 30 years of age, inflammatory forms of parodontal diseases prevail and they manifest themselves in the form of various gingivitis forms, in the age group of 30 years and older, the inflammatory process is accompanied by destructive processes and manifests by parodontitis of varying severity [29].

Thus, it can be stated that the steady trend of parodontal diseases progression that has formed recently requires a deep and comprehensive study.

The educational material consistently presented in this textbook will help students to master the basic level of the subject and successfully pass the exam in orthopedic dentistry.

## ***Lesson №1***

---

***Training subject:*** “Parodontium diseases. Classification. Etiology. Pathogenesis. Aims of orthopedic treatment. The main symptoms of parodontites. Determining the nosological forms of parodontium diseases — focal parodontitis (traumatic node) and generalized parodontitis”.

***The purpose of the lesson:*** to introduce students to the concept "dental parodontium". To consider the classification of parodontium diseases. To study the features of etiology and pathogenesis. To determine the aims of orthopedic treatment. To analyze the main symptoms of parodontium diseases — focal one and generalized one.

***Practical lesson plan:***

1. Checking the initial level of knowledge.
2. Explaining the next clinical material with a demonstration of thematic patients.
3. Independent students' work on the topic of the practical lesson.
4. Generalizing the lesson's content with ongoing monitoring the retention of the lesson materials.
5. Hometask with a recommendation of educational literature.

***Control questions on the topic of the lesson:***

1. Parodontium of the teeth. Anatomical structure, physiological and biomechanical features of parodontium tissues.
2. Classification of parodontium diseases.
3. Etiology and pathogenesis of parodontium diseases.
4. Tasks of orthopedic treatment for parodontium diseases.
5. Determining the nosological forms of parodontium diseases — focal parodontitis (traumatic node) and generalized parodontitis.
6. The main symptoms of parodontites.

***Lesson content:***

***The concept of "parodontium"*** combines a complex of anatomical structures: the gum, the periodontium, the alveolar bone tissue and the dental root cementum, having common sources of innervation and blood

supply and forming an integral whole, connected by their common function and origin.

The collective *concept of "parodontium diseases"* includes diseases in which the complex of parodontium tissues is affected.

Periodontal (parodontium) tissue diseases are one of the main mass lesions of the dental system.

Parodontium diseases are quite diverse in their origin and mechanism of development, clinical course. Some diseases develop mainly with the manifestation of chronic or acute and subacute inflammation, others are characterized by dystrophic changes. In the parodontium, deep inflammatory, destructive and dystrophic processes can simultaneously develop, as well as diseases that are tumor or tumor-like in nature.

Such a variety of forms and course patterns resulted in development of the classification for parodontium diseases.

The first attempt to create a unified classification in the 30s of the twentieth century was made by the International Organization for the Study of Periodontal Diseases (ARMA). *It was based* on the classification of the German researcher Veski. Its main advantage is a clear description given to the clinical manifestations of each of the existing forms of periodontal diseases, and the disadvantage is the variety of terms that do not always reveal the pathogenetic essence of the disease.

In the 40-50s in our country, **the classifications** developed by A. I. Evdokimov, I. G. Lukomsky, I. O. Novik, E. E. Platonov, Ya. S. Pekker were widely used, later appeared the classification of MMSN (Moscow Medical Dental School), N. F. Danilevsky, G. D. Ovrutsky, the 1st Leningrad Medical Institute, etc.

The decision of the XVI-th Plenum of the All-Union Scientific Society of Dentists in 1983 approved the classification of parodontium diseases for the use in scientific, pedagogical and therapeutic work. It is based on the nosological principle used by the WHO.

Classification of parodontium diseases

*I. Gingivitis* is an inflammation of the gums caused by adverse effects of local and general factors and occurring without violating the integrity of the dento-gingival attachment.

*Form:* catarrhal, hypertrophic, ulcerative.

*Severity:* mild, moderate, severe.

*Course:* acute, chronic, aggravated, remission.

*Prevalence:* localized, generalized.

*II. Parodontitis* is an inflammation of parodontium tissues, characterized by a progressive destruction of the periodontium and the bone. *Severity:* mild, moderate, severe.

*Course:* acute, chronic, aggravated (including abscessing), remission.

*Prevalence:* localized, generalized.

*III. Parodontosis* is a dystrophic damage of the parodontium .

*Severity:* mild, moderate, severe.

*Course:* chronic, remission.

*Prevalence:* generalized.

*IV. Idiopathic diseases with progressive lysis of parodontal tissues* (Papillon Lefevre syndrome, histiocytosis X, gammaglobulinemia, diabetes mellitus (uncompensated), etc.).

*V. Parodontomes* are tumor-like processes in the parodontium.

The main advantage of the classification is a differentiated approach to various diseases of parodontal tissues in accordance with the clinical and morphological features of the pathological process: inflammation, dystrophy, tumors.

Pathological processes in parodontal tissues are attributed to groups I and II of diseases, which are determined by a mandatory manifestation of classical inflammatory signs in them: exudation, alteration and proliferation.

Group I includes numerous diseases that affect only soft parodontium tissues; group II is made of parodontitis, in which the entire parodontium complex is involved in the process: the gum, periodontium, the alveolar bone (process), tooth tissues.

Group III is made by parodontosis — a generalized dystrophic process of all parodontium tissues.

Group IV combines the processes in the parodontium that accompany a number of common diseases in the body.

The differential method, which makes the basis of this classification, also takes into account the etiological factors of each disease, which facilitates selecting an optimal, strictly individualized complex for the effective treatment and prevention of parodontium diseases. The uniformity of defining the main symptoms of each disease accepted in the

classification facilitates the choice of the necessary range of complex therapeutic measures: the form, severity, the clinical course, prevalence.

Most researchers attribute parodontium diseases, in particular parodontitis, to polyetiological, developing, subfrontal, sagittal, fronto-sagittal, parasagittal and cross ones. It can be single or multiple.

**Generalized parodontitis** develops in a long-term chronic course of the process, often against the background of systemic diseases. In this case, the entire dento-facial system is affected. The main symptom-complexes inherent in generalized parodontitis are secondary gingivitis, formation of periodontal pockets, progressive resorption of the alveolar bone, formation of traumatic occlusion. The intensity of these signs depends on the severity of the pathological process.

The main radiographic findings of generalized parodontitis are various degrees of the cortical layer destruction, resorption of the interalveolar septa, osteoporosis of the spongy substance of the alveolar bone, moderate broadening of the periodontal fissure.

## ***Lesson №2***

---

**Training subject:** "Methods for studying the condition of the parodontium and their diagnostic significance: probing, determining the mobility of teeth, conducting the Schiller-Pisarev test, occlusiography, studying the orthopantomogram, filling in the odontoparodontogram and its analysis."

**The purpose of the lesson:** to introduce students to the methods of examining patients with parodontium diseases of the teeth.

**Practical lesson plan:**

1. Checking the initial level of knowledge;
2. Explaining the next clinical material with the demonstration of thematic patients.
3. Independent students' work on the theme of the practical lesson.
4. Generalizing the lesson's content with ongoing monitoring the retention of the lesson materials.
5. Hometask with a recommendation of educational literature.

***Control questions:***

1. Methods of studying the condition of the parodontium
2. Probing, parodontometry. Determining the degree of teeth mobility.
3. Conducting the Schiller-Pisarev test, occlusiography.
4. The study of orthopantomograms, filling in the odontoparodontogram and its analysis.

***Lesson content:***

The purpose of examining a patient with a parodontium pathology is to assess the general condition of the body, to give the clinical characteristics of parodontium, to identify general and local etiological and pathogenetic factors, to determine the form, the stage and the course of the disease. The most complete information enables to correctly diagnose the disease, to plan effectively its comprehensive treatment and prevention. The necessary complex of differential diagnostic indicators is obtained by the doctor by a thorough history taking, a detailed clinical examination, using laboratory methods and examination findings received by specialists of another medical profile.

***Pasthistory:*** passport data are specified — profession, the presence or absence of occupational hazards, the nature of nutrition, past illnesses, stressful conditions, environmental, social, living conditions, compliance with oral hygiene, etc. It is necessary to find out the hereditary connection: whether the closest relatives (parents, sisters, brothers) suffer from such diseases, whether there were bad habits in the past or there are bad habits currently. It is specified whether the patient is prone *to* allergic reactions.

If necessary, the patient should undergo an examination and receive the opinion of other specialists. In case of parodontium diseases, consultations of a therapist, an endocrinologist, a neurologist, an allergist and other doctors are most often needed.

***History of the present illness:*** complaints related to the processes that developed in the oral cavity are determined, as well as the time of their onset, the dynamics of development, their possible causes; whether there were exacerbations, what were their causes.

The information obtained during history taking is often crucial for clarifying the diagnosis.

***During the examination***, attention is paid to the general appearance, facial expression, the presence of pathology on the visible skin, in the soft tissues of the maxillofacial region, the presence or absence of asymmetry, the condition of the lips, the angles of the mouth, the character of articulation, the degree of mouth opening, etc.

When examining the vestibule of the mouth, attention is paid to its depth. To determine the depth, the distance from the gingival margin to its bottom is measured with a graded instrument. The vestibule is considered shallow if its depth is not more than 5 mm, medium-8-10 mm, deep-more than 10 mm.

***The gum.*** During the examination, the condition of the gums is assessed from the vestibular and lingual sides. The color, consistency, bleeding, depth of the gingival crevice, the integrity of the dentogingival junction, the condition and severity of the interdental papillae, the presence of periodontal pockets and discharge from them are noted. When assessing the dentition, the relationship of the teeth, the presence of plaque, dental deposits, the shade of enamel, the shape of crowns, the degree of their attrition and displacement, the formation of tremas and diastemas, the presence of traumatic occlusion, mobility, etc. are taken into account.

*A periodontal pocket* is formed due to a damage to the integrity of the dentogingival junction under the influence of submerged epithelial growth, destruction of the ligamentous apparatus, the alveolar bone and the cement of the tooth root. An extraosseous periodontal pocket (without destruction of the alveolar bone) and a bone pocket (with destruction of the alveolar bone) are distinguished. The presence of periodontal pockets, their depth and extent in parodontium pathology largely determine the clinical presentation of the disease, the doctor's tactics in the treatment of a particular nosological form, as well as the prognosis. The condition of the periodontal pocket is judged on the basis of determining its depth, the presence of exudate and ulceration. When determining the depth, its physiological features should be taken into account.

True and false periodontal pockets are distinguished. In a false periodontal pocket, the integrity of the dentogingival junction is not

violated, and the depth of the pocket is increased due to swelling or hypertrophy of the gum.

The depth of the periodontal pocket is measured with a graded carver or a blunt probe with millimeter divisions applied to them. For the same purposes, a special tool is also used — a parodontometer. The instrument is inserted into the pathological pocket and slowly advanced until a slight feeling of support appears. Depending on the group of teeth, it is recommended to carry out several measurements: in the area of molars, two from the buccal and palatolingual surfaces and one from the distal and medial ones. In the area of premolars, incisors and canines, 4 measurements are carried out — one on each surface. The obtained data are recorded in Arabic numerals or special conventional signs in the dental formula and odontoparodontogram. Sometimes, to clarify the localization and the depth of the periodontal pocket, radiography is performed having introduced radiopaque pins, turundas impregnated with special solutions or suspensions: radiopaque substances (barium sulfate, iodolipol, cardiostat, verografin, urotrast, etc.).

The depth of the periodontal pocket is assessed taking into account the age, the extent of tooth eruption. When measuring the depth, in addition to the distance from the gingival margin to the bottom of the pocket, the exposure of the root surface due to gum retraction (the distance from the enamel-cement border to the top of the gingival papilla) is taken into account.

*The degree of dental mobility* is associated with the severity and the depth of destruction of the dental ligamentous apparatus and the character of the inflammatory process in the parodontium. Dental mobility is the most pronounced in the vertical form of the alveolar process resorption and an aggravated course of inflammation, elimination of which is usually accompanied by a significant decrease in mobility, stabilization of the teeth. Mobility is characterized by the direction and degree of the tooth deviation from the normal position and is determined by palpation, using tweezers or special devices.

***There are three degrees of dental mobility:***

1 - the tooth is inclined in the vestibular-oral (labial-lingual) direction within the width of the tooth cutting edge (1-2 mm);

2 - in addition to the mobility indicated above, there is mobility in the medio-distal direction;

3 - in addition to these displacements, the tooth is visually movable in the vertical direction.

*The Schiller-Pisarev* test is used to detect an inflammatory process in the gum. It is based on the intravital staining of glycogen with an iodine-containing Lugol solution, the amount of which increases in the epithelium during inflammation. With glycogen accumulation, the color intensity increases. The gingival margin is treated with a cotton swab moistened with a solution of the following composition: iodine 1 g, potassium iodide 2 g, distilled water 40 ml. The inflamed part of the gum instantly stains into transitional tones from light brown to dark brown, depending on the degree of inflammation.

The test can be used to determine the extent of inflammation and the volume (boundaries) of surgical intervention in gingivectomy, papillotomy, curettage of periodontal pockets, to identify subgingival dental deposits, it can serve as an objective test for evaluating the effectiveness of treatment, for differential diagnosis, etc. Clarification of occlusal contacts can be carried out using occlusiograms and diagnostic models. *Occlusiography* is a method of obtaining occlusal contacts on thin wax plates (you can use bugel wax) in teeth coming together. Normally, in orthognathic occlusion, a linear contact is determined on a strip of wax in the the frontal teeth area and a point contact is determined in the lateral teeth area, but the thinnest wax layer remains in these areas. If there are excessive contacts in a particular area, holes are formed in the wax (if there are no contacts, no imprint is formed in the wax). After applying a wax plate to the diagnostic model, the areas of excessive contacts are transferred to the teeth models with a pencil and the grinding zones are determined.

Also, occlusal paper of various thicknesses (from 8 to 200 microns) is used to determine supercontacts. Initially, occlusal contacts are studied using occlusal paper with a thickness of 200 microns; after selective grinding, they are brought to the appearance of a linear contact in the frontal teeth area and a multiple point contact in the lateral teeth area (with occlusal paper with a thickness of 8-12 microns).

In parodontites, due to the significant mobility of the teeth, obtaining occlusiograms and especially their interpretation are difficult, that is why V. N. Kopeikin proposed to carry out selective grinding of teeth in two stages. At the first stage, it is necessary to carry out preliminary grinding

of the teeth in the area of pronounced supercontacts. The second stage should be carried out after the immobilization of the teeth with various splinting therapeutic structures.

*Orthopantomography* (panoramic tomography) gives the opportunity to get the image of both jaws on the same film. The study is carried out on an orthopantomograph. An X-ray tube and a cassette with a film having the shape of a half-cylinder are placed at opposite ends of one axis strictly opposite. The X-ray tube and the film, rotating, describe a concentric incomplete circle around the patient's head, which is fixed motionless. The cassette with the film, rotating around the patient's head, also moves around its vertical axis, while the X-ray radiation consistently illuminates various parts of the jaws that are fixed on the film. The X-ray tube can be rotated around three axes, which enables to provide perpendicular and orthoradial directions of the rays with respect to the area being photographed. Panoramic tomography helps to obtain a single-step image of the entire dentoalveolar system as a single functional complex. The disadvantage of this method is a not very clear image of the bone structure, mainly in the area of the front teeth.

*During X-ray examination*, periodontal resorptive processes of various severity degrees are detected in patients with parodontitis. In the initial stage, in some cases, no changes are detected in the interdental septa. Sometimes there are "translucences" of their tops — the initial process of osteoporosis, destruction of the cortical plate at the top of the septum. In the future, an increase in the looping of the spongy bone in the area of the tops, disappearance of the tops, the expansion of the periodontal fissure are revealed. The progression of the process leads to gradual disappearance of the septal bone tissue at a different level in relation to the root. This allows, as well as when using probing, to distinguish *four degrees of bone tissue destruction*:

I degree — initial, without the disappearance of bone tissue along the length;

II degree - reduction in the height of interdental septa by % - 1/3 of the root length;

III degree - reduction of height by 1/2 of the root length;

IV degree — resorption of the interdental septa along the length of 3/4 or more of the root length.

Simultaneously with the increase in bone tissue resorption, the severity of osteoporosis signs increases in the preserved areas of interdental and inter-root septa, the periodontal fissure expands.

Parodontitis is characterized by the fact that bone tissue destruction develops only in the alveolar process of the upper jaw or in the alveolar part of the lower jaw. The structure of bone tissue in other parts is not altered. Depending on the genesis of the disease, destructive processes in the bone tissue develop in separate areas or throughout the entire dentition (focal, or localized; diffuse, or generalized, parodontitis).

Panoramic radiography and orthopantomography enables to get only an overview of the level of destructive processes. With the help of intraoral radiography, it is possible to obtain more accurate data on the structure of bone tissue and to determine the processes developing in it in more detail.

***Kurlandsky's odontoparodontogram*** is a graphic image of damage to the dentition and parodontium, which gives a visual picture reflecting the condition of the supporting apparatus of the preserved teeth. Compilation of an odontoparodontogram is carried out in order to identify the condition of the dental-facial system, i.e. the functional stability of the supporting apparatus of each tooth to the load. An odontoparodontogram is obtained by entering the information about each tooth and its supporting apparatus in a special drawing-table.

In varying degrees of atrophy of the socket (according to X-ray examination), the endurance of abutment teeth changes, which is calculated using conditional coefficients. The coefficients of parodontium's endurance to the load correspondingly decrease with an increase in the atrophy of the socket. In the 1st degree atrophy, there is a reserve of parodontium's endurance. In the 2nd degree socket atrophy, the reserve forces of the parodontium are reduced, and in the 3rd degree atrophy, there is a pronounced functional insufficiency. In case of the 4th degree atrophy, the tooth is to be removed. When the reserve forces disappear, the pathological process becomes particularly acute.

After filling in the corresponding columns for the teeth of the upper and lower jaws, the actual preservation degree for the supporting apparatus of the entire dentition is entered in figures. These data make it possible to navigate in the power relations between the upper and lower dental arches, between individual groups of teeth. The main task of

orthopedic treatment is to equalize the power relations between dental arches of the upper and lower jaws.

Further tactics of the doctor is aimed at eliminating the existing traumatic nodes in certain areas of dental arches.

## ***Lesson №3***

---

***Training subject:*** "Examination of patients with parodontal diseases. Taking impressions: studying diagnostic models, detecting premature contacts. Treatment plan. The basics of choosing the designs of therapeutic devices".

***The purpose of the lesson:*** teaching students to work with diagnostic models in a medium anatomical articulator for further preparation of a comprehensive treatment plan for patients with parodontium diseases.

### ***Practical lesson plan:***

1. Checking the initial level of knowledge;
2. Explaining the next clinical material with the demonstration of thematic patients.
3. Independent students' work on the theme of the practical lesson.
4. Generalizing the lesson's content with ongoing monitoring the retention of the lesson materials.
5. Hometask with a recommendation of educational literature.

### ***Themes studied earlier and necessary for conducting the lesson:***

1. Anatomy of parodontal tissues.
2. Etiology, pathogenesis, clinical presentation of parodontal tissue diseases.
3. Features of the clinical presentation in parodontitis and parodontosis
4. The main orthopedic measures carried out by a doctor in patients with parodontal tissue diseases.

### ***Questions for monitoring the results of material retention:***

1. The purpose of selective teeth grinding.
2. How is selective grinding planned?
3. Describe the procedure for selective teeth grinding. What does the final dental preparation include?

***Control questions on the theme of the lesson:***

1. Taking impressions and studying diagnostic models in a medium anatomical articulator.
2. Identification of supercontacts and comparison with occlusiogram data. The method of selective grinding on models.
3. Formulation of the diagnosis. Preparation of a comprehensive treatment plan for parodontitis.
4. The basics of choosing the designs of therapeutic devices.

***Lesson content:***

Orthopedic treatment in parodontal diseases is carried out in order to prevent, eliminate or weaken the functional overload of the parodontium, which at a certain stage of the disease is one of the main pathological factors that determine the course of the disease. Elimination or reduction of the functional overload puts the parodontium in new conditions, in which inflammation and dystrophy develop more slowly. Thanks to this, therapeutic measures become more effective.

In order to reduce the functional overload and facilitate performing its function for the the affected parodontium, it is necessary:

Various methods of teeth grinding are known, but the most popular methods are those of Jenkelson and Schueller. According to the latter method, occlusion correction occurs both in the central, and in the anterior and lateral occlusions.

Grinding is preceded by extraction of teeth with a high degree of pathological mobility, causing a pronounced deformation of the dentition. Then planning of grinding is carried out. To do this, first visually, and then with the help of a softened wax strip or copy paper, those areas that are subsequently subjected to grinding are specified. At first, such manipulation is performed only in the position of the central occlusion, and then in the anterior, lateral and posterior occlusions.

In grinding, only the configuration of the cusps changes, the cusps themselves, as a rule, are not ground.

The most intensively colored areas or tissues are ground in those places where a perforation is formed on the wax, depending on what is used as a diagnostic tool. At this, the anatomical tooth shape should not be grossly distorted and grinding of tissues should be distributed equally on opposing teeth. This is especially true for the cutting edges of the front teeth. Grinding is completed after removing the obstacles for smooth movements of the lower jaw and after obtaining multiple contacts in the central occlusion position with the help of occlusion paper with a thickness of 8-12 microns.

In case of deep incisor overlap, deep bite, upper or lower progeny, retrognathia, macro - and micrognathia, it is recommended to carry out selective grinding mainly in the central, anterior and posterior occlusions. In case of cross-bite, narrowing of the dentitions, reverse relationship of the lateral teeth in the transversal plane, the central and lateral occlusions are the preferred positions for registering and eliminating premature and blocking interdental contacts.

Selective teeth grinding is carried out with the help of high-speed machines and centering of shaped heads, grinding is preceded by application or infiltration anesthesia, and if necessary - premedication.

The tops of the supporting cusps (palatine upper and buccal lower) are not ground, since they provide stability of the central occlusion and preserve the occlusal height. Protective buccal upper cusps protect the mucous membrane of the cheek, and the lingual lower cusps protect the tongue from getting between the teeth. The slopes of cusps that interfere with dynamic occlusion, the non-abraded areas of the teeth are ground, the fissures are deepened, sharp edges are smoothed.

In the central occlusion, the teeth are not removed from contact. To avoid excessive grinding of the teeth, it is advisable to first grind the teeth on the model, make a plan for grinding in the oral cavity, decide whether it is possible to eliminate supercontacts by grinding or other methods of occlusive correction are necessary.

Reconstruction of occlusal teeth surfaces is recommended to be carried out in the following sequence.

A wax plate or occlusal paper is placed on the dentition of the upper or lower jaw, the patient articulates, and areas of wax perforation are marked on the teeth with a pencil through the wax. Then the wax is removed and the marked areas are ground. When making an

occlusiogram in the centric jaw relation, it is advisable to apply a wax plate on the dentition of the upper jaw in the area of lateral teeth. The doctor places his thumb of the right hand on the lower front teeth and moves it distally (passive displacement) by lightly pressing on the lower jaw. Active displacement of the lower jaw to the centric jaw relation is carried out by the patient without the doctor's help. The horizontal position of the patient relaxes the masticatory muscles and contributes to the correct placement of the lower jaw in the centric jaw relation.

Normally, the occlusiogram should have uniform translucent areas of wax throughout the occlusal surface of the teeth.

When grinding on the working side (the side of the lower jaw displacement), a group contact of at least the buccal cusps of the upper and lower premolars or molars should be achieved, in the anterior occlusion - the maximum possible number of front teeth (incisors and canines), in the central occlusion — multiple fissure-cusp contact of the teeth of both sides, in the centric jaw relation — bilateral contact of the slopes of the chewing teeth cusps (2-3 pairs).

During sliding movements from the central occlusion to the centric jaw relation (posterior contact position), those slopes of the cusps that prevent uniform sagittal movements of the lower jaw should be ground.

Grinding of teeth in the mouth in lateral occlusions and orthognathic occlusion is carried out according to Jenkelson method: on the working side, the 1 and 2 classes of the occlusal surface are ground (external slopes of the buccal cusps on the lower lateral teeth and internal slopes of the buccal cusps on the upper lateral teeth, external slopes of the palatine cusps on the upper lateral teeth and internal slopes of the lingual cusps on the lower lateral teeth), and on the balancing side, the III class of the occlusal surface is ground (internal slopes of the buccal cusps on the lower lateral teeth and internal slopes of the palatine cusps on the upper lateral teeth).

The rule of grinding incisors and canines in anterior occlusion: the cutting edges and the palatine surface of the upper teeth, the cutting edge and the vestibular surface of the lower teeth are ground while maintaining contacts in the central occlusion. The inner slopes face the central fissure. Then the occlusal contacts of the lateral teeth are checked during the anterior movements of the lower jaw, grinding the supercontacts on the

anterior slopes on the cusps of the lower lateral teeth and on the distal slopes of the cusps on the upper lateral teeth.

When the lower jaw moves, premature contacts are detected on the distal slopes of the lower lateral teeth cusps and on the anterior slopes of the upper lateral teeth cusps.

Selective grinding of teeth usually takes 3-4 visits in a week. After each procedure, the teeth are treated with sodium fluoride or fluorine varnish.

Patients with malocclusion are observed to have atypical contacts in the central, anterior and lateral occlusions, that is why the areas of the occlusal teeth surface that are subject to grinding are determined individually for each patient.

In parodontitis, which developed against the background of a deep bite, shortening of the frontal teeth group is aimed at removing the blocking areas of the teeth in a sagittal movement of the lower jaw and reducing separation of the masticatory teeth group in anterior occlusion. Grinding is carried out along the cutting edge and by the contacting surfaces of the teeth when the jaw moves forward. In case of parodontitis, grinding is carried out to remove the concentration of occlusive contacts on individual teeth, and not to exclude them from occlusion. Grinding is carried out under visual control when the lower jaw moves anteriorly, to the right and to the left and it is stopped when pain sensations appear. First, the central incisors are shortened, then the lateral ones and (if necessary) canines. After shortening the teeth, removal of the blocking areas starts. To do this, the articulation paper folded in half is placed between the teeth and, fixing the loose teeth with the fingers, the patient is asked to move the lower jaw forward, then to the right and to the left. Places of greatest contact leave traces on the articulation paper. After visual inspection of these areas during the movements of the jaw, they are ground. If the paper leaves a uniform trace on all contacting surfaces, and visual inspection confirms the absence of blocking areas, grinding is stopped. All the ground areas are smoothed with a rubber polish.

The final stage is the treatment of the wound surfaces of the teeth. Firstly, they are polished, and secondly, calcium ions are impregnated in them with the help of electrophoresis. Thirdly, they are covered with fluorine varnish or a protective varnish.

Complications in selective teeth grinding: a decrease in occlusal height, orthodontic effect of tooth displacement, hypersthesia of hard dental tissues, excessive load on the parodontium after grinding the cusps of the teeth, removal of some teeth from contact and overload of the parodontium in other teeth. That is why to use correctly this method of occlusal correction, it is necessary to know the basics of the biomechanics of the dental-maxillofacial system, to analyze occlusal contacts in the oral cavity, as well as on diagnostic models, to comply with certain rules.

IN SAGITTAL MOVEMENT OF THE JAW	TO CHANGE THE DEGREE OF INCISOR OVERLAP	IN THE LOWER JAW DISPLACEMENT	IN THE LOWER JAW DISPLACEMENT TO THE LEFT
<p>In the area of the front teeth: grinding of the vestibular surface of the lower incisors, starting from the incisor edge by 1/3 of the clinical crown length within the enamel, grinding the incisor edge by 1/5 of the clinical crown length on the upper incisors. In the area of the lateral teeth: the lateral teeth of the lower jaw are not ground, the lateral teeth</p>	<p>In the area of the frontal teeth: grinding of the vestibular and incisor edges on the lower incisors at an acute angle to the longitudinal axis by 1-2 mm, grinding of the incisor edge by 1/4 of the clinical crown length on the upper incisors. In the area of the lateral teeth: the lateral teeth of the lower jaw are not ground, the lateral teeth of the upper jaw are not ground to size.</p>	<p>In the area of the front teeth: the lower incisors are not sliced, the upper incisors are not ground off. In the area of the lateral teeth.</p> <ol style="list-style-type: none"> <li>1. Slicing the vestibular surface of the buccal cusp on the lower lateral teeth within the enamel.</li> <li>2. Slicing the tip of the lingual cusp on the lower teeth within the enamel.</li> </ol> <p>Grinding the top</p>	<p>In the area of frontal teeth: the lower incisors are sliced, the upper incisors are not ground off. In the area of the lateral teeth</p> <ol style="list-style-type: none"> <li>1. When grinding the lingual slope of the buccal cusp of the lower lateral teeth within the enamel</li> <li>2. Grinding the buccal slope of the palatine cusp of the upper lateral teeth within the enamel.</li> </ol>

of the upper jaw are not ground to size.		of the palatine slope of the buccal tubercle of the upper lateral teeth within the enamel, the surface of the palatine tubercle within the enamel of upper lateral teeth.	
--	--	---	--

## ***Lesson №4***

---

***Training subject:*** "Complex therapy of parodontites. Classification of splints. Types of dental arch stabilization. Temporary splinting".

***The purpose of the lesson:*** introducing students to the complex treatment of parodontites; studying the types of dental arches stabilization; mastering the methods of temporary teeth splinting.

***Practical lesson plan:***

1. Checking the initial level of knowledge;
2. Control of the initial level of knowledge.
3. Explanation of the next clinical material with a demonstration of patients and the opportunities of using temporary splinting structures.
4. Independent work of students with patients;
5. Discussion of patients' curation;
6. Control of the lesson materials' assimilation;
7. Summary of the lesson;
8. Home task, literature.

***Control of the initial level of knowledge:***

1. Describe the concept of "parodontium".
2. Classification of parodontium diseases.
3. The role of traumatic occlusion in the development of parodontal diseases.

***Control questions on the topic of the lesson:***

1. Complex treatment of parodontites.
2. Classification of splints.
3. Requirements for splints.
4. Types of dental arch stabilization.
5. The method of temporary splinting as a therapeutic stage aimed at creating the stability of teeth and dental arches in general.

***Lesson content:***

*A complex method of treatment* provides for identifying the etiological factors, a clear definition of the pathogenetic mechanism and the leading links of the disease. This is necessary to determine the means of etiotropic and pathogenetic therapy and to develop a specific plan for the complex treatment of parodontium.

The main principle of parodontitis treatment is implementation of complex therapy, which includes local conservative, physiotherapeutic, surgical and orthopedic treatment, as well as it provides for the use of general effects on the entire body. Local treatment consists in eliminating exogenous factors in the oral cavity, and it is carried out simultaneously with the use of other methods (therapeutic, physiotherapeutic, surgical and orthopedic) (LDS 1).

The treatment includes:

- ✓ elimination of local exogenous factors that cause and support the inflammatory process (removal of dental deposits, overhanging fillings, correction or replacement of orthopedic prostheses, etc.);
- ✓ effects on the inflammatory process (local and general anti-inflammatory treatment);
- ✓ stimulation of the body's reactivity;
- ✓ desensitizing therapy;
- ✓ general health-improving therapy.

Orthopedic methods in complex treatment of parodontal diseases make it possible to normalize occlusive relations, to remove the traumatic effect of masticatory pressure, to restore the continuity of the dentition, to preserve loose teeth during the disease exacerbation and to improve the quality of therapeutic and surgical treatment methods.

Orthopedic treatment of parodontal diseases is associated with the use of various splints designs. The therapeutic effect of a particular splint is based on the laws of biomechanics (LDS 2).

With the help of splints, it is possible to join the teeth into a common system, which is a single whole when perceiving masticatory pressure. In this way, the following is achieved: teeth immobilization, redistribution of the load on the teeth with a healthy parodontium or on the alveolar process, a uniform distribution of masticatory pressure on the remaining teeth, elimination of aesthetic defects, normalization of masticatory function and speech.

#### ***Classification of splints.***

- ✓ by duration — permanent and temporary;
- ✓ by the method of fixation — removable and non-removable;
- ✓ by manufacturing method — laboratory and clinical manufacturing;
- ✓ by materials — metal, plastic, composite, combined;
- ✓ by manufacturing method — cast, stamped, soldered, made by polymerization, ligature;
- ✓ by design — different types of crowns, bridges, clasp and plate prostheses.

In order to perform the role of a medical device, the splint must meet the following requirements:

- ✓ create a solid block of groups of teeth, limiting their movements in three directions: vertical, vestibular-oral and medio-lateral (for anterior teeth) and medio-distal (for lateral teeth);
- ✓ be stable and firmly fixed on the teeth;
- ✓ not to have an irritating effect on the marginal parodontium;
- ✓ not to interfere with medical and surgical therapy of the parodontal tissues;
- ✓ not to have retention points for food retention;

- ✓ not to create blocking points with their occlusal surface when the lower jaw moves;
- ✓ not to make speech worse;
- ✓ not to cause gross violations of the patient's appearance.
- ✓ be easy to be applied and removed from the dentition;
- ✓ evenly redistribute the masticatory pressure on the retainer teeth and replace the defect of the dentition.

Combining different prosthesis designs, teeth with different periodontal conditions, it is necessary to use the reserve forces of many teeth or even the entire dentition. Taking into account the presence of reserve forces, their absence or development of functional insufficiency is the basis for choosing the design of splinting devices and prostheses.

The type of dentition stabilization (the length of the splint) is determined based on the study and analysis of the patient's odontoparodontogram and orthopantomogram. Depending on the splint's localization, there are sagittal, frontal, fronto-sagittal, para-sagittal stabilization and stabilization through an arc.

Immobilization of the teeth, in which splints are located in the antero-posterior direction on the lateral teeth, is called lateral, or *sagittal*. The sagittal type of stabilization enables to create a block of teeth that is resistant to forces developing in the vertical, transversal and medio-distal directions. If the frontal part of the dentition is joined by to the lateral stabilization, then this type of stabilization is called *fronto-sagittal*.

In a dental arch with bounded defects in the lateral sections, its sagittal stabilization can be enhanced by a transverse one. This type of stabilization is called *para-sagittal*. Usually, such stabilization is achieved by an arch prosthesis, i.e. a combination of fixed devices with a removable splinting prosthesis. In such a splinting system, the lateral load that occurs on one side is distributed to the opposite side as well.

If the dentition is continuous, it can be combined into a single block with a continuous or multi-section splint. This type of stabilization is called *stabilization through an arc*. Stabilization through an arc mobilizes the reserve forces of the periodontium in all teeth.

Based on the fact that in generalized parodontitis, the reserve forces of the periodontium are reduced in all teeth and the degree of reduction is different, it is impractical to stabilize individual groups of teeth. In focal parodontitis, it is permissible to use one of stabilization methods.

The splint should include teeth that do not have reserve forces of the parodontium, and teeth that have preserved them. The following rule should be followed: the sum of coefficients in a functionally significant group of teeth with unaffected parodontium included in the splint should be 1.5-2 times higher than the sum of coefficients in teeth with affected parodontium and be equal to half of the sum of coefficients in opposing teeth participating in the act of mastication.

A *splint is* a device for immobilization (complete immobility or a significant decrease in mobility) of a group or all teeth of the dentition. A splint used for a certain period of treatment is called a temporary splint.

*The method of temporary splinting* is used for generalized or focal chronic parodontitis during the period of exacerbation and during the entire period of complex treatment until application of a permanent splinting device. Temporary splinting makes it possible to eliminate the traumatic effect of pathological mobility and masticatory function — one of the pathogenetic mechanisms that supports hemodynamic disorders in periodontitis. The splint provides an even distribution of masticatory pressure forces between the parodontium of teeth included in the splint, creates peace to the affected tissues and contributes to the effectiveness of pathogenetically justified and symptomatic therapy. The use of a temporary splint enables to break the pathogenetic chain: inflammation - impaired blood supply — dystrophy— the function of chewing and helps to improve trophicity in parodontal tissues, eliminate the inflammatory process. In addition, it is not recommended to carry out surgical methods of parodontium treatment without prior immobilization of the teeth.

***Temporary splints must meet the following requirements:***

- ✓ securely fix all teeth;
- ✓ be easy to be applied and removed from the dentition;
- ✓ evenly redistribute the masticatory pressure on retainer teeth and replace the defect of the dentition.
- ✓ not to interfere with drug therapy and surgical treatment;
- ✓ not to injure the gingival mucosa;
- ✓ be easy to manufacture and affordable.

The simplest method of temporary splinting is the use of ligature splints. In addition, temporary splints can be made of fast-hardening

acrylic plastics in the laboratory or directly in the oral cavity, as well as from composites or photo-cured composite materials (oral, vestibular, multi-section, by Mareu, Frigof, etc.).

Temporary tires can be metal: bent, cast, stamped mouth-guards with occlusal windows. You can use a multi-section splint that is fixed on the teeth with the help of mechanical cyanoacrylate glue of the MK-6, MK-9 brand or with the help of various adhesive systems of the Veriolink type (IVOCLAR company).

**LDS 1. Complex treatment of parodontitis**

Therapeutic treatment	Surgical treatment:	Physiotherapeutic treatment.	Orthodontic treatment	Orthopedic treatment
Removal of dental deposits; stimulating medicinal therapy; desensitizing therapy; anti-inflammatory therapy.	Curettage of dentogingival pockets; simple gingivectomy; radical gingivectomy.	Electrophoresis; diathermocoagulation; UHF therapy; gum massage; vacuum treatment.	Treatment of vestibular displacement of teeth, tremas, diastemas; treatment of vestibular displacement, complicated by partial adentia; treatment of Popov-Godone phenomenon in parodontitis.	Selective grinding of the teeth; immediate prosthetics; temporary splinting; permanent splinting.

**LDS 2. Laws of biomechanics used in orthopedic dentistry:**

Method name	Characteristics of biomechanical principles
Biomechanical methods of using splints.	<ol style="list-style-type: none"> <li>1. A splint attached to the teeth, due to its rigidity, restricts the scope of their mobility. The teeth can only move together with the splint and in one direction.</li> <li>2. The splinting structure, combining all the front and all the lateral teeth into a block, unloads their parodontium when biting or chewing food.</li> <li>3. The load in the splinting block is primarily perceived by the teeth that have a lesser pathological mobility, they unload the teeth with a more affected parodontium.</li> <li>4. The teeth are arranged in an arch, the curvature of which is more pronounced in the anterior part, so the splinting structure located in through an arch is more resistant to external forces than a splint located linearly.</li> <li>5. The order of masticatory load distribution depends on the point of forces application.</li> <li>6. In a linear arrangement of the splint, splint vibrations are possible when the teeth have 1 or 2 degrees of mobility.</li> </ol>

## ***Lesson №5***

---

***Training subject:*** "Focal parodontitis. Etiology. Pathogenesis. Clinical presentation. Orthopedic methods of treatment for focal parodontitis. Justifying the design of the splint (or splint-prosthesis) and its length based on the examination data and analysis of odontoparodontograms. Requirements for medical devices in the treatment of focal periodontitis".

***The purpose of the lesson:***

1. To analyze the etiology, pathogenesis, clinical presentation and treatment of focal parodontitis.
2. To analyze the types of dentition stabilization, splints designs - removable, non-removable and combined.

***Practical lesson plan:***

1. Checking the initial level of knowledge;
2. Explaining the next clinical material with the demonstration of thematic patients.
3. Independent students' work on the theme of the practical lesson.
4. Generalizing the lesson's content with ongoing monitoring the retention of the lesson materials.
5. Hometask with a recommendation of educational literature.

***Control questions on the topic of the lesson:***

1. Etiology. Pathogenesis.
2. Clinical presentation and orthopedic methods of treatment for focal parodontitis.
3. Analysis of a parodontogram.
4. Clinical and biological bases for the choice of the treatment method for preserved dentition and in partial adentia.
5. Justification of splints or prosthesis structures and their length based on the data of parodontograms analysis.
6. Types of stabilization and their justification.
7. Structures of tires and splint prostheses: fixed, removable, combined.
8. Requirements for non-removable devices in the presence of focal parodontitis. Conducting a clinical stage, depending on splinting device or prosthesis design.

***Control of the initial level of knowledge:***

1. The leading symptoms in the clinical presentation of partial adentia.
2. The concept of functional teeth overload.
3. Clinical manifestations of secondary malocclusion deformities. The Popov-Godone phenomenon.
4. Traumatic occlusion and its types.
5. Characterize the degree of teeth mobility by Emtin.
6. Health-improving measures in the oral cavity carried out before dentoprosthetic rehabilitation (therapeutic, surgical).

7. Characteristics of dental arch defects and their classification (Kennedy, Gavrilov).

***Lesson content:***

In focal periodontitis, the inflammatory and dystrophic processes in periodontal tissues are detected in individual teeth or their groups and are localized within the parodontal tissues. Local factors play the main role in the development of focal periodontitis: microbial plaque, formation of sub - and supra-gingival dental deposits, the absence of interdental contacts, overhanging edges of fillings, poorly made dentures, anomalies of teeth position and shape, malocclusion, chronic trauma and overload of teeth. Exogenous factors also affect the functional state of parodontal tissues — poor hygienic care, smoking. An important role is played by occupational hazards, stress, injuries and bad habits. Acute focal periodontitis begins with the appearance of spontaneous, not very intense pain when chewing, bleeding gums, mobility of a tooth or a group of teeth. As a rule, it is usually preceded by gingivitis of various etiologies or medical intervention. Radiographs show an expansion of the periodontal fissure.

The force of masticatory pressure acting on the tooth is transformed into the ligamentous apparatus, cellular elements, periodontal vessels and is transmitted to the inner surface of the alveolar wall, the spongy substance and the outer compact plate. Under the influence of functional loads, all tissue elements of the parodontium become deformed and, first of all, the ligamentous apparatus of the periodontium and bone tissue. The functional load and the resulting elastic deformation of parodontal tissues are functional stimuli of the vascular and nerve elements of the parodontium. In turn, the neurovascular apparatus plays an important role in the reflex regulation of masticatory pressure force. When a vertically directed force is applied to the tooth, elastic deformations develop in the socket walls, causing tension (compression) of these walls, which is different at different levels. The elastic limit of bone tissue depends on the structure of the bone substance and the degree of its mineralization. The degree of bone tissue deformation in the socket walls of the teeth is also determined by the presence of neighboring teeth. The integrity of contact points on approximal surfaces of the teeth contributes to a partial redistribution of the load from one tooth to its neighboring teeth and

thereby reduces the degree of socket walls deformation of the submerged tooth. If the contact points are violated, the deformation of the socket walls increases, the horizontal component of the masticatory pressure has a detrimental effect on the periodontal tissues, while in some areas there is excessive compression, and in others - stretching. When the periodontium is compressed, there is a partial or complete cessation of blood flow in individual capillaries. In the compression areas, resorption processes prevail. If constant pressure in one direction is not removed, the resorption processes increase and are manifested by the formation of a periodontal pocket, and then by a visible decrease in the height of teeth socket walls in the compression areas. Bone tissue resorption is explained not only by the influence of masticatory pressure forces. The condition of the jaws bone tissue is directly related to the vascular bed, it depends on the metabolism in the entire body, as well as on the state of the neuroreceptor system and local blood circulation. In periodontitis, the process of socket walls resorption proceeds much faster, since atrophy is combined with an inflammatory process in the parodontium, leading to even greater mobility of the teeth.

The degree of socket walls deformation and the load on the parodontium increase, the amplitude of tooth displacement increases, which further aggravates atrophic processes. At a certain stage of the disease development, functional overload becomes one of the leading factors in the pathogenesis, resulting in traumatic nodes, traumatic occlusion and traumatic articulation.

Functional conditions of existence are created for various groups of teeth. There are a functional center, a traumatic node and a non-functioning link — an atrophic block.

***The functional center is*** a group of opposing pairs of teeth, chewing food with which occurs without periodontal injury (due to the presence of physiological reserve forces). The functional center is unstable and can move from the functional load. Because of its mobility, it is also called a relative functional center.

***The atrophic block*** is a non-functioning link. These are teeth that do not have opposing ones. Atrophic processes develop in the parodontium and the pulp of teeth devoid of opposing teeth. Deformations most often develop in the atrophic link (the Popov-Godone phenomenon).

**A traumatic node** is a section of the dentition with the greatest manifestation of functional insufficiency. The teeth forming the traumatic node are in a state of functional overload. The traumatic node by localization can be frontal, sagittal, frontosagittal, parasagittal and crossed. It can be single or multiple. Clinical symptoms — displacement of the teeth, deformation of the occlusal curvature and all the symptoms characteristic of parodontitis. By etiology, a direct and a reflected traumatic node are distinguished. **A direct traumatic node** can occur both in an intact dentition and in partial adentia. A direct traumatic node results from the impact of masticatory load at the site of the etiological factor action.

**The reflected traumatic node** occurs in other areas (outside the site of the etiological factor action).

Treatment of parodontal disease is carried out in a complex and consists of general and local one. General treatment is aimed at stimulating the body's reactivity, anti-inflammatory, desensitizing and general therapy. Local treatment consists in eliminating the etiological factors and conducting complex treatment using therapeutic, physiotherapy, surgical and orthopedic methods. They provide for:

1. elimination of local factors that cause and support the inflammatory process;
2. treatment of the inflammatory process;
3. stimulation and activation of parodontal vessels.

Orthopedic methods make it possible to normalize occlusal relations, to remove the traumatic effect of masticatory pressure, to restore the continuity of the dentition.

Orthopedic treatment aims to eliminate or weaken the functional load (overload) of the parodontium.

**The tasks of orthopedic treatment are:**

1. Removal of traumatic factors.
2. Functional balancing of teeth groups, uniform distribution of masticatory pressure among the remaining teeth with the most affected parodontium at the expense of teeth with a healthy periodontal disease.
3. Restoration of the anatomical shape and function of the dental-maxillary system, its transformation into a continuous whole.

For the treatment of parodontal diseases in orthopedic dentistry, the following treatment methods are used:

- ✓ selective grinding of dentitions;
- ✓ temporary splinting;
- ✓ orthodontic treatment;
- ✓ immediate insertion denture prosthesis;
- ✓ permanent splinting with the restoration of the continuity of the dentitions by making splints-prostheses.

***Indications for functional teeth slicing are:***

- 1) premature contacts that have arisen as a result of uneven attrition or lack of attrition of individual teeth groups, changes in the position of teeth due to parodontium damage;
- 2) the presence of contact only on individual teeth when closing the jaws in the central, lateral and anterior occlusions;
- 3) contacts that block the movement of the lower jaw in different directions.

The therapeutic effect of grinding is to eliminate or significantly reduce the horizontal component of masticatory pressure which is harmful to the affected parodontium, to reduce the spatial displacement of the tooth, to lessen the compression of the periodontal vessels, and therefore, to remove factors that worsen blood circulation and tissue trophism. Functional slicing is used both in the initial and in the advanced stage of the process.

Normalization of occlusal and articulatory relations of dentitions is achieved by:

1. shortening of protruding teeth;
2. reducing the degree of incisal overlap;
3. selective slicing of cusps' slopes.

Normalization of occlusal relations should not reduce the occlusal vertical dimension. Traumatic points are detected when the lower jaw moves with the help of copy paper. Slicing is carried out by a less harsh method. On the teeth of the upper jaw, the slopes of the buccal cusps are recorded, on the lower teeth — the slopes of the lingual cusps. Shortening of the tooth crown is carried out with a diamond disk with a reliable fixation of the tooth. Slicing of the tooth protruding from the occlusion equalizes the relation of its crown and root parts of it and places the tooth

in a favorable functional position. After leveling the occlusal surface, the sliced areas are treated with fluorine-containing pastes, and then polished. In cases where there are defects in dentitions and there is a possibility of secondary teeth displacement, their stripping must be completed with prosthetic measures.

To achieve success in the treatment of not a disease in general, but a disease in a particular patient, it is necessary to take into account the peculiarities of the disease course in this person, to outline and implement a strictly individual treatment plan, using a combination of various therapeutic agents. A correct choice of the treatment method and the use of optimal structures prevents and suspends further destruction of the dental-maxillary system by destructive processes and makes it possible to fully implement modern orthopedic treatment of focal parodontitis. This method, in particular, is splinting.

*Splinting* refers to the connection of movable teeth into a block with the help of some orthopedic medical device. Equator crowns, half-crowns, crowns, rings, caps soldered together can serve as splints. With the help of splints, it is possible to join the teeth into a common system, which is a single whole when perceiving masticatory pressure. The splint achieves immobilization of the teeth and redistribution of the load on the teeth.

*Depending on the splint localization, the following types of stabilization are distinguished:*

1) frontal; 2) sagittal; 3) parasagittal; 4) frontosagittal; 5) arch stabilization. The type of dentition stabilization, i.e. the length of the splint, is determined based on the clinical situation and the analysis of the parodontogram.

*Devices used for the treatment of focal periodontitis should:*

1) to reduce the traumatic effect of masticatory pressure and the pathological mobility of the teeth involved in the pathological process;

2) normalize the pathomorphological relations of parodontal tissues during the period of performing mastication function due to a uniform distribution of masticatory pressure on the parodontium of affected and splinted teeth with an unaffected parodontium;

3) restore the functional physiological balance between the parodontal tissues of the damaged area and the opposing group of teeth;

4) restore the anatomical shape of the teeth

and dental arches, their topographic and anatomical relationships

The length and type of the splint depends on the degree of preservation of the reserve forces of the teeth affected by parodontitis, and the functional relations of the opposing teeth. At this, the following rules should be followed: the sum of the teeth functional significance coefficients (according to the parodontogram) with an intact parodontium included in the splint should be 1.5-2 times higher than the sum of the coefficients of teeth with an affected parodontium and be equated to the sum of the coefficients of opposing teeth involved in biting and chewing food, taking into account the maximum placement of an alimentary bolus between 3-4 teeth. In this case, a single system of equator crowns, faced crowns (metal-ceramic or metal-composite), adhesive splints can be used as a splint.

If focal parodontitis spreads to the entire functionally oriented group of teeth (anterior, lateral) and these teeth do not have reserve forces (atrophy has reached half of the socket wall length or more), it is necessary to switch to a mixed type of stabilization. For the group of chewing teeth, the parasagittal type of immobilization is the most appropriate; for the group of front teeth, stabilization through an arc with premolars involvement is most appropriate.

Indications for the use of parasagittal stabilization and removable types of splints are cases of parodontal damage to distally located teeth, both in intact dentitions and in defected. In intact dentitions and focal parodontitis of the II and III degrees in the group of maxillary frontal teeth, an effective way to reduce tooth mobility is the use of endodonto-endosteal implants inserted into the bone tissue of the periapical zone through the tooth canal. This type of splinting makes it possible to strengthen teeth with mobility of the II-III degree.

Parodontitis in combination with partial secondary adentia aggravates the pathological process in parodontal tissues. If orthopedic treatment is not provided in a timely manner, all teeth can be lost. Orthopedic treatment is carried out with the use of various splints - prostheses.

Fixed splints-prostheses include bridge-like prostheses. In parodontitis, dental bridgeworks are used only in the presence of bounded edentulous space, taking into account the functional capabilities of

parodontal tissues in retainer teeth. The use of cantilever bridges should be excluded.

Removable cast splinting prostheses are therapeutic structures of arch dentures.

The design of removable splinting prostheses and devices that provide horizontal unloading of teeth is based on double denture clasps and multi-section clamps with vestibular and oral coverage of all teeth. Immersion of the prosthesis into the mucous membrane is prevented by the use of occlusive onlays. For these purposes, Ney clamp system is most often used.

Removable splinting prostheses, the design of which includes stamped and cast caps and beams that rest on a group of teeth and unite them, provide both vertical and horizontal unloading of teeth.

The *combined splinting method* is the use of fixed and removable types of prostheses.

The character of fixed splints and splinting prostheses combination depends on the specific clinical presentation. The remaining teeth are splinted with some kind of non-removable splint, and the defect is repleted with a clasp prosthesis or another type of prosthesis.

To perform the therapeutic purpose, the splints must ***meet the following requirements:***

1. create a solid block of groups of teeth, limiting their movements in three directions: vertical, vestibular-oral and medio-lateral (for anterior) and antero-posterior (for lateral teeth);
2. be stable and firmly fixed on the teeth;
3. not to have an irritating effect on the marginal parodontium;
4. not to interfere with medical and surgical therapy of the gingival pocket;
5. not to have retention points for delaying food;'
6. not to create blocking points with their occlusal surface when the lower jaw moves;
7. not to make speech worse;
8. not to cause gross violations of the patient's appearance. Orthopedic treatment is carried out in combination with
9. therapeutic, surgical, physiotherapy methods.

## **Lesson №6**

---

**Training subject:** "Generalized parodontitis. Etiology. Pathogenesis. Clinical presentation. Treatment.

**The purpose of the lesson:** to study the issues of etiopathogenesis, clinical presentation and treatment of generalized parodontitis.

**Practical lesson plan:**

1. Checking the initial level of knowledge;
2. Explaining the next clinical material with the demonstration of thematic patients.
3. Independent students' work on the theme of the practical lesson.
4. Generalizing the lesson's content with ongoing monitoring the retention of the lesson materials.
5. Homework with a recommendation of educational literature.

**Control of the initial level of knowledge:**

1. What is the complex method in the treatment of patients with chronic generalized parodontitis?
2. Types of dental arch stabilization.
3. Kurlandsky's odontoparodontogram (purpose and essence of the method).

**Control questions on the topic of the lesson:**

1. Generalized parodontitis. Etiology. Pathogenesis.
2. Clinical presentation of generalized parodontitis.
3. Analysis of radiographs in generalized periodontitis.
4. Justification for choosing design features of tires and prostheses.
5. Orthopedic treatment of generalized parodontitis in intact dental arches. Types of medical devices.
6. Orthopedic treatment of generalized parodontitis in partial adentia. Types of medical devices.

**Lesson content:**

***Generalized parodontitis is a destructive and inflammatory disease*** that affects both jaws and is characterized by an inflammatory process in the parodontium and a destructive process in the bone tissue of the jaw body and the alveolar process. The disease is mainly endogenous in nature. The leading role in the development of parodontitis is assigned to neurovascular disorders in the maxillofacial region. A certain role in the origin of parodontitis is played by immunological changes in the body. Local factors that contribute to aggravation of the disease are of significant importance as well.

Consequently, two factors dominate in the issue of parodontal diseases etiology: general and local.

**The *general etiological factors*** include: hormonal disorders and diseases (diabetes, S-trisomy syndrome, Papillon-Lefevre syndrome, disorders of the pituitary - adrenal system); violations of metabolic processes, accompanied by a generalized damage to the vascular network of the entire body, leading to microangiopathy in the parodontium (hypertension, atherosclerosis, infectious diseases); diseases of the nervous system (epilepsy, parafunctions and others), diseases of blood, genetic predisposition and hereditary diseases, allergic diseases, pronounced general dystrophic processes that reduce immunity and result in changes in the body's defenses.

***Local factors*** include: poor hygienic oral care, tobacco smoking, occupational hazards. Local factors also include pathogenic flora in the oral cavity, formation of bacterial toxins (cariou teeth, roots, chronic tonsillitis, etc.), various types of violations of articulatory balance, poor-quality dentures, anomalies of the position and shape of teeth, malocclusion pathology. Therefore, we can talk about a polyetiological genesis of dental parodontal diseases.

The pathogenetic mechanisms of parodontal diseases are vascular shifts in the form of disorders in the parodontium's microcirculatory bed. With the help of modern examination methods (rheography, radioisotope methods, etc.), it is shown that the initial factor in the pathogenesis is microcirculation disorders, resulting first in functional, and later in organic changes in the vascular walls in periodontal tissues. This leads

first to tissue hypoxia, and then to significant dystrophic disorders. In addition, perverted or increased immunological reactivity of the body in parodontitis has been proven, which indicates the role of this factor in the pathogenesis of parodontal diseases. Therefore, when drawing up a treatment plan, the main

attention should be paid to these disturbed mechanisms. Only under this condition, therapeutic measures will be pathogenetic in nature.

***The main symptom*** complexes inherent to generalized parodontitis are: symptomatic gingivitis, supra- and subgingival tartar, bleeding gums, tooth mobility, periodontal pocket, progressive resorption of the alveolar bone, formation of traumatic occlusion. The intensity of these signs depends on the severity of pathological process.

In generalized parodontitis of mild degree, the depth of periodontal pockets is up to 3.5 mm. In parodontitis of moderate severity — up to 5 mm. The clinical signs of inflammation and destruction of parodontal tissues are aggravated. The teeth become loose (I, II degree), their necks and partially their roots are exposed, the height of the maxillary alveolar process (the alveolar part of the lower jaw) is unevenly reduced to 1/3 - 1/2 of the roots length. In a severe degree of parodontitis, all symptoms increase, abscesses form, the depth of periodontal pockets is more than 6-8 mm, the mobility of teeth of the II-III degree. The loss of bone tissue of the alveolar process reaches 1/4 or more of the tooth root length.

***The main radiographic findings*** of generalized parodontitis are various degrees of the cortical layer destruction, resorption of interalveolar septa, osteoporosis of the spongy substance of the alveolar bone, moderate expansion of the periodontal fissure. These manifestations of the pathological process in different course of the disease are ambiguous.

Radiologically, in mild chronic periodontitis, there is a resorption of the interalveolar septa up to 1/4 of tooth root length, the absence of a compact plate at the top of the alveolus and adjacent lateral sections.

In moderate periodontitis, the X-ray image clearly shows resorption of the alveolar bone up to 1/2 the root length, resorption follows a vertical, horizontal and mixed type of atrophy; there is an increase in the looping of the spongy bone.

In severe periodontitis, the X-ray image determines resorption of the alveolus by 3/4 or more of the root length.

It should be noted that panorex radiograph and orthopantomography enable to study the overview ideas about the level of destructive processes. With the help of intraoral radiography, it is possible to obtain more accurate data on the structure of bone tissue and to determine the processes developing in it in more detail.

When choosing a splint design, one should proceed from the functional value of each tooth and the functional relations between maxillary and mandibular dentitions.

The topography and the size of the defect in the dentitions, along with the condition of the dental parodontium bordering on the defect, and all the remaining teeth determine the character of stabilization and the type of splint-prosthesis.

The orthopedic treatment of parodontal diseases is based on the use of parodontal reserve forces, alignment of functional - power relations and their redistribution between groups of teeth and dental arches in general. To do this, it is necessary to conduct a thorough analysis of the patient's odontoparodontogram.

Orthopedic treatment for parodontal diseases can be carried out while preserving all the teeth in the dental arch. In these cases, we speak about splinting, immobilization of all teeth with fixed or removable medical devices.

If parodontal diseases are accompanied by defects in the dentitions, then the task of orthopedic treatment additionally includes the need to restore missing teeth. For these purposes, structures, which are called splints-prostheses are used.

The issue of which dental prosthesis to choose for the treatment of parodontal diseases (removable or non-removable splints) can only be solved as follows: it is indicated to use the type of immobilization which, taking into account all the individual characteristics of the disease course, will make it possible to suspend further development of the pathological process.

Manufacturing the splinting structures for permanent splinting requires a thorough analysis and examination of the dental-maxillary system in every patient with parodontitis.

***When planning the design of a splinting prosthesis, it is necessary:***

- a) distribute the masticatory load taking into account the condition of the supporting apparatus of each tooth;
- b) select the supporting, splinting and fixing elements, and the methods of their connection (rigid, labile, semi-labile);
- c) take into account the aesthetic requirements of the patient.

It is possible to regulate the transfer of masticatory pressure from the intermediate part of the splint-prosthesis by increasing the number of retainer teeth, leveling the angulation of the crown part in retainer teeth, reducing the width of artificial teeth, changing the design features of the clamps and increasing the prosthetic basis. Leveling the functional capabilities between the maxillary and mandibular dental arches can be achieved through reasonable use of removable and non-removable splints-prostheses.

The following condition must be observed: the non-removable splint should not overload the opposing teeth.

Orthopedic treatment of generalized parodontitis in preserved dental arches varies depending on the severity of the disease.

In a mild degree, when the dystrophic process involves less than 1/4 of the socket wall length, there is a minor decrease in the reserve forces of the dental arches. Splinting in this condition of the dental-maxillofacial system is not indicated. Local and general restorative treatment is recommended, as well as selective grinding of teeth (according to indications).

In atrophy of more than 1/4 of the socket wall length, the reserve forces decrease, the pathological mobility of the teeth increases. In this case, orthopedic treatment faces the following tasks:

1. achieve redistribution of masticatory pressure applied to individual teeth, to the entire dentition;
2. combine all the teeth of each jaw into a block;
3. eliminate pathological mobility;
4. prevent teeth displacement.

The splints used should provide immobilization through an arc in combination with parasagittal stabilization.

In the treatment of generalized parodontitis of moderate and severe degree, one-piece removable splints are used, consisting of a single system of various modifications of molar denture clasps and multi-link clasps with vestibular processes. When designing such splints,

modifications of Ney system clamps should be purposefully used in order to reduce the effect of traumatic components of masticatory pressure on the parodontium of each tooth. Orthopedic treatment should eliminate the effect of not only horizontal, but vertical components of masticatory pressure on the teeth as well. To do this, the design of removable splints must include cast elements that overlap the occlusal teeth surface (for example, Elbrecht splint). It is possible to use combined splinting — fixed and removable. If more than 1/2 of the length of the tooth socket wall is affected by atrophy, the best effect is given by the use of non-removable splints in combination with removable ones, which provide parasagittal stabilization and redistribution of the vertical component of the masticatory pressure. Non-removable splints include: equator splints, cap splints, Kopeikin interdental splint, Mamlock splint (whole piece inlays with dental posts),

solid-cast crowns, faced with composite materials. The elements of the connection between the links of the anterior and lateral teeth are attachments, Roach clasps, etc.

In the treatment of parodontitis, "Maryland-system" type splints and its variants are used [Kopeikin V. N., 1988; Popov N., 1984] — these are non-removable tires (fixed on the teeth with composite materials), which are an expanded oral multi-link clamp with a system of occlusive overlays, throw-over elements and vestibular processes.

In generalized parodontitis, complicated by partial adentia, orthopedic treatment is difficult due to a decrease or complete absence of reserve forces of the dental parodontium and a violation of power relationships between the dentitions. The prosthesis splints used in this case should balance the distribution of masticatory pressure between individual teeth or their functionally oriented groups on each of the jaws and evenly redistribute the masticatory pressure from the base of the prosthesis to the remaining teeth.

***The tasks of orthopedic*** treatment are: a) combining all the teeth of each jaw into a single block; b) uniform distribution of all components of masticatory pressure on the parodontium of the remaining teeth; c) eliminating additional load on the parodontium of teeth bordering on the defect; d) restoring the function of chewing in all functionally oriented groups of teeth.

Patients with parodontal diseases and a violation of the dentition continuity should be divided into two groups: the first includes patients with bounded defects, and the second — with unilateral or bilateral free-end edentulous space.

When the defect is located in the frontal part of the dentition, prosthesis is carried out with the help of bridge-shaped prostheses fixed on crowns.

If there is a large defect in the frontal part, the remaining lateral teeth are splinted with non-removable splints, and the defect is replaced with a removable prosthesis. For small and medium-sized unilateral and bilateral bounded lateral defects, splinting is carried out with bridge-like prostheses reinforced on crowns, taking into account the functional capabilities of the retainer teeth. The edges of the crowns should not go under the gum, leaving the gingival pocket open for medical and surgical therapy.

In large bounded defects and a significant parodontal lesion, the use of single teeth for fixing the clasps of clasp prostheses is unacceptable, since it will further increase their overload.

If the teeth are very mobile, it is necessary to include additional elements in the design of the clasp prosthesis in the form of: continuous multi-section clasps, throw-over clasps (Jackson), double (according to Bonville), claw-like processes, masticatory pressure absorbers. The purpose of the shock absorber is to reduce or completely remove vertical, horizontal and overturning components of masticatory pressure transmitted from the saddle part of the prosthesis to the supporting teeth. The longer the spring branches and the higher the elastic modulus of the alloy are, the greater is the magnitude of the damping torque. The load absorber can be a spring branch from the shoulder of the clamp to the frame of the base. A kind of spring, or a load absorber, can be the arch of the splinting prosthesis.

Combined types of splints are used — stationary prostheses fixed on a group of front teeth and premolars, and a clasp prosthesis replacing a group of molars. The fixed and removable parts can be connected using various claspless fixing systems (attachments, telescopes, etc.).

## **Lesson №7**

---

**Training subject:** "Indications for tooth extraction in parodontal diseases. Temporary removable plate prostheses - immediate insertion dentures. Indications for manufacturing, purpose. Fixed and removable immediate insertion prostheses. Preparation of plaster models for the manufacture of immediate insertion prostheses. The method of splinting. Subsequent stages of patients' treatment. The importance of early prosthetics in parodontal diseases".

**The purpose of the lesson:** to teach students the methods of manufacturing immediate insertion prostheses.

**Practical lesson plan:**

1. Checking the initial level of knowledge;
2. Explaining the next clinical material with the demonstration of thematic patients.
3. Independent students' work on the theme of the practical lesson.
4. Generalizing the lesson's content with ongoing monitoring the retention of the lesson materials.
5. Homework with a recommendation of educational literature.

**Control of the initial level of knowledge:**

1. Name the indications for multiple tooth extraction.
2. Name the indications for immediate prosthetics and splinting.
3. Name the clinical and technical stages of manufacturing immediate splint-
4. prostheses.
5. How to prepare models for immediate insertion prosthetics of the frontal group of teeth?
6. How to prepare models for immediate insertion prosthetics in the area of lateral teeth?
7. How is an immediate insertion prosthesis treated before being applied in the oral cavity?
8. In what cases is the use of non-removable structures of immediate prostheses indicated?

## 9. Therapeutic effect when using immediate prostheses.

### ***Lesson content:***

During preparation of the oral cavity for prosthetics with removable and non-removable prostheses, it is often necessary to resort to tooth extraction with a diseased parodontium. When solving this issue, it is necessary, firstly, to keep in mind the functional value of the dentition, and secondly, the possibility of using it in orthopedic treatment. Determining the functional value of a tooth requires first of all calculating the degree of its pathological mobility and the depth of the parodontal lesion, that is, the degree of atrophy of the alveolar process bone tissue. The degree of pathological mobility of a tooth is closely related to the value of atrophy of the alveolar process bone tissue. But in some patients, for example, with dystrophic forms of parodontal disease (parodontosis), such a connection is not traced.

In a pathological mobility of the third degree and resorption of the bone tissue of the alveolar process for more than 3/4 of the tooth root length, when the compensatory capabilities of the parodontium are completely exhausted, the teeth must be removed. In addition, teeth with II-III degree of mobility, having periapical foci of chronic inflammation, are also subject to removal.

The operation of tooth extraction in humans is accompanied by significant anatomical and functional changes. Excessive load on the remaining teeth, violations in the act of chewing, speech, aesthetic defects that appear in the postoperative period have a negative impact on the parodontal tissues and on the patient himself. Extraction of even one or more front teeth sharply disrupts pronunciation of sounds, complicates professional activity, is accompanied by psychological trauma.

One of the most effective ways to eliminate defects resulting from tooth extraction is the method of immediate prosthetics. This method consists in the fact that the prostheses are prepared before surgical intervention, and then, immediately after tooth extraction, they are fitted on the jaw. Such prostheses are called immediate prostheses.

Scientific studies have shown that the processes of bone tissue regeneration and socket healing under an immediate laminar denture proceed much faster.

When preparing the alveolar crest on the model, it is recommended to give the alveolar crest a smooth, oval shape in the frontal area and a trapezoidal shape in the area of masticatory teeth.

In parodontitis, the layer of plaster removed does not exceed 1-1.5 mm. On the upper jaw in the frontal part, the plaster is removed only from the vestibular side. On the lower jaw in the frontal part, the plaster is removed evenly along the ridge of the alveolar process.

In the area of masticatory teeth, a layer of plaster is removed from the model along the edges of the sockets, slightly rounding the edges.

After the model is prepared, the laboratory stages of manufacturing an immediate prosthesis are performed. Before applying the prosthesis, it is kept for 15-20 minutes in a 3% solution of hydrogen peroxide, the areas of the base adjacent to the wound surface are treated with a 5% alcohol solution of iodine.

The next day, the patient must come to the dentist's for correcting the prosthesis.

After the introduction of the prosthesis into the oral cavity, the patient is recommended:

1. rinse the mouth after eating and wash the prosthesis before going to bed;
2. not to remove the prosthesis during 10-12 first nights after tooth extraction.

The use of immediate prostheses makes it possible to preserve the height of the facial lower part, which can be changed as a result of extracting teeth that hold the occlusal height.

Along with immediate prosthetics, prostheses can be made after surgery, before a complete healing of the tooth socket — early prosthetics (5-7 days after tooth extraction).

The first method (direct prosthetics) is used in cases where the state of teeth mobility enables to get an impression without the fear of removing the tooth when taking the impression. The second method (early prosthetics) is used for abscessing processes, the need to remove a significant number of loose teeth, when there are difficulties in obtaining an impression and it is not possible to determine the magnitude of possible changes in the shape of the alveolar process after surgical interventions.

### ***Stages of manufacturing an immediate prosthesis:***

1. choosing a prosthesis design;
2. obtaining impressions and models;
3. determining centric occlusion and fixing models in the articulator using the face-bow;
4. preparing models;
5. laboratory stages of prosthesis manufacturing;
6. fitting and applying a prosthesis in the oral cavity after tooth extraction

When preparing the alveolar crest on the model, it is recommended to give the alveolar crest a smooth, oval shape in the frontal area and a trapezoidal shape in the area of masticatory teeth.

In parodontitis, the layer of plaster removed does not exceed 1-1.5 mm. On the upper jaw in the frontal part, the plaster is removed only from the vestibular side. On the lower jaw in the frontal part, the plaster is removed evenly along the ridge of the alveolar process.

In the area of masticatory teeth, a layer of plaster is removed from the model along the edges of the sockets, slightly rounding the edges.

After the model is prepared, the laboratory stages of manufacturing an immediate prosthesis are performed. Before applying the prosthesis, it is kept for 15-20 minutes in a 3% solution of hydrogen peroxide, the areas of the base adjacent to the wound surface are treated with a 5% alcohol solution of iodine.

The next day, the patient must come to the dentist's for correcting the prosthesis.

After the prosthesis is introduced into the oral cavity, the patient is recommended: 1) to rinse the mouth after eating and wash the prosthesis before going to bed; 2) not to remove the prosthesis for the first 10-12 nights after tooth extraction; 3) to try to chew food, first eat soft food in small portions, and then harder and larger portions; 4) to read aloud to restore speech quickly. Only in a month after the teeth extraction, it is necessary to adjust the basis with an auto-polymer resin.

In cases where bridge-like or splinting devices are indicated after tooth extraction, it is possible to use fixed bridge structures of immediate prostheses. At this, the method of manufacturing prostheses is in principle identical to the generally accepted one, as is the nature of treating the retainer teeth.

In recent years, immediate temporary splints or permanent splints-prostheses have been made in parodontites. Immediate removable splinting clasp prostheses and non-removable bridge-shaped splinting prostheses are also used. Before manufacturing an immediate permanent splinting prosthesis, a thorough and comprehensive examination is carried out, the teeth to be extracted are determined, and the optimal splint design is chosen. An appropriate treatment of the teeth that are retainers for this splint type is carried out. Impressions are obtained, the centric occlusion is determined and the splint support elements are made. If these are crowns or three-quarter crowns, the impressions should be double-layered, which enables to determine the exact degree of the crown edge immersion in the gingival crevice, especially from the side of the tooth to be extracted.

If during the follow-up of a temporarily fixed non-removable splint it is established that the intermediate prosthesis part made in the group of front teeth does not touch the mucous membrane (a large atrophy has developed), then the degree of fitting is specified with the help of a fast-setting plastic. Having processed and polished the specified areas, the splint is again temporarily (for 1 week) fixed for control.

Following-up the patients using both removable and non-removable immediate prostheses indicate good adaptation due to differential irritations, accelerated epithelialization and wound healing, restoration of masticatory efficiency. Tooth extraction against the background of systemic parodontal diseases, as a rule, leads to an increase in the severity of teeth functional overload. In order to prevent possible complications and preserve the remaining teeth, immediate prosthetics should be used more widely, since this allows preventing the development of the most severe forms of traumatic occlusion.

## ***Lesson №8***

---

***Training subject:*** “Imposition of complex splints and splints-prostheses. Rehabilitation of patients with parodontitis at the stages of orthopedic treatment. Prognosis. The role of oral hygiene in patients with the presence of dentures in parodontal diseases”.

***The purpose of the lesson:*** to teach students the methods of manufacturing and applying complex splints and splints-prostheses in the oral cavity in patients with parodontal diseases,

***Practical lesson plan:***

1. Checking the initial level of knowledge;
2. Explaining the next clinical material with the demonstration of thematic patients.
3. Independent students' work on the theme of the practical lesson.
4. Generalizing the lesson's content with ongoing monitoring the retention of the lesson materials.
5. Hometask with a recommendation of educational literature.

***Control of the initial level of knowledge:***

1. What are the features of introducing prosthetic splints into the oral cavity and their fixing on the teeth?
2. The main orthopedic measures carried out by the dentist in patients during repeated visits after applying splints-prostheses.
3. Maintaining fixed and removable splints and splints-prostheses in complex treatment.
4. Complications and errors in splinting teeth, imposition of complex splints and splints-prostheses.

***Lesson content:***

Complex splints and splints-prostheses are carefully examined before being inserted into the oral cavity. During the inspection, attention is paid to the quality of processing, correctness of the manufacture of clamps, arches, splinting devices and plastic bases.

Clamps and splinting devices must be well processed and sanded, and their end parts must be rounded. After examination, the prosthesis-splint is introduced into the oral cavity and carefully, without much effort, put on the teeth.

The retaining arms of the clasps, regardless of their number, should freely slip through the clinical contour height, and occlusal onlays, mesiodistal elements, claw-like and other devices are located in their beds. At this, they should not create super contacts and block the movement of the lower jaw.

After that, it is necessary to teach the patient to introduce splinting medical devices into the oral cavity and put them on the teeth. Such training eliminates breakdowns and deformation of the parts of the splint-prosthesis.

In order to avoid the development of a carious process in the teeth at the place of attachment of molar denture clasps and splinting medical devices, good hygiene of the oral cavity and the prosthesis is necessary.

Getting used to clasp prostheses is slower than to fixed structures.

In complex treatment of periodontitis, the prognosis can be favorable only if the patient is followed-up in a dispensary, and the patient strictly follows the doctor's instructions on individual prevention and personal oral hygiene.

Poor and insufficient oral care in the presence of orthopedic devices contributes to additional accumulation of food residues, microflora procreation, deposition of plaque and calculus. At this, plaque, and then calculus are deposited not only on the teeth, but on splints and prosthetic splints as well. All this creates conditions for exacerbation of already existing inflammatory phenomena in the parodontal tissues. The methods of complex treatment used in this case do not give the desired result. Because of this, the attending physician should warn the patient about the need for more thorough oral hygiene, since in the presence of various splinting medical structures, due to the presence of hard-to-wash areas under the prostheses, self-cleaning of the oral cavity is significantly reduced.

Of great importance is the quality of treating the medical device – polishing metal and plastic elements of the splinting prosthesis. In poor-quality polishing, the rate of microflora colonization on prostheses increases several times, which can result in a complication of the pathological process in parodontal tissues.

If there are minor tremas between the teeth, it is recommended to grind the approximate surfaces of the teeth, creating a parallelism between them, which makes it free to wash out food residues. Mechanical cleaning of natural teeth remaining in the oral cavity and that of non-removable splints-prostheses is carried out using a brush and paste. Toothpastes foam well, dissolving mucus and soft plaque on natural teeth and non-removable splints-prostheses. Cleaning natural and artificial teeth should be regular and carried out 2 times a day – in the morning and

in the evening. The patient must be convinced of mandatory rinsing the oral cavity after every meal.

Cleaning splints and prosthetic splints should be careful. Carefulness when performing this work prevents possible deformations of splinting devices. The most dangerous in this regard are solid-cast splints, which, if handled roughly, can not only deform, but also break.

In the complex treatment of parodontitis in patients with concomitant general somatic pathology, the dentist needs to cooperate closely with a general practitioner. Only with this approach to treatment, parodontitis can have a favorable prognosis.

## ***Lesson №9***

---

***Training subject:*** “Orthopedic treatment with clasp prostheses with a system of fixation on molar denture clasps in partial adentia and parodontal diseases”.

### ***The purpose of the lesson:***

1. Studying the indications for the manufacture of clasp prostheses, studying the design features of clasp prostheses’ elements, analysis of fixation system in clasp prostheses;
2. analysis of indications and contraindications for the use of Ney system clasps, their design features.
3. introducing students with the sequence of conducting and features of clinical and laboratory stages in the manufacture of cast clasp prostheses with a clamp.

### ***Practical lesson plan:***

1. Checking the initial level of knowledge;
2. Explaining the next clinical material with the demonstration of thematic patients.
3. Independent students’ work on the theme of the practical lesson.
4. Generalizing the lesson’s content with ongoing monitoring the retention of the lesson materials.
5. Hometask with a recommendation of educational literature.

***Control questions for checking the initial level of knowledge:***

1. Characteristics of dental arch defects.
2. Classification of dental arches defects.
3. Positive and negative qualities of bridge and laminar dentures.
4. Stages of obtaining impressions from the jaws.
5. The retaining clamp, its constituent elements and their purpose.
6. Types of retaining clamps.
7. Lines of clasps.
8. The main structural materials used in clasp prostheses manufacturing.

***Control questions on the topic of the lesson:***

1. Clinical indications for treatment with clasp prostheses;
2. Characteristics of structural elements of the clasp prosthesis;
3. Clasp attachment system;
4. Concepts of diagnostic models;
5. Requirements for the tooth crown chosen for placing a support-retaining clasp;
6. Ney system clasps, designs, indications for use;
7. The way of introduction and removal of the clasp prosthesis;
8. Connection of the clasp with the prosthesis. The reaction of parodontium in the retainer teeth and the “saddle bed reaction” during masticatory load.
9. What are the advantages and disadvantages of the casting method on a fire-resisting model?
10. List the main structural materials used in manufacturing clasp prostheses .
11. Why is the mold dried and fired?
12. Classify the alloys used in orthopedic dentistry.
13. What casting methods are known to you?
14. The composition and tyhe purpose of facing masses.
15. How is the model prepared for duplication?

***Lesson content:***

When choosing the design of a clasp prosthesis in parodontitis complicated by partial adentia, you can use the Kennedy classification. It distinguishes between four classes and the corresponding subclasses for each class.

1. class — two-sided free-end saddles.
2. class — one-sided free-end saddle.
3. class – bounded defects in the lateral sections (depending on the size of the defect).
4. class — a bounded defect in the frontal part.

The design of the clasp prosthesis is determined by the number of remaining teeth of the jaw, the condition of their parodontium and the type of occlusion. It is necessary that there are less than 5-6 teeth on the jaw. A deep occlusion and a small interalveolar space in the area of the defect is a relative contraindication for orthopedic treatment with clasp prostheses.

In a clasp prosthesis, there are: the basis (bases) (sometimes these parts of the prosthesis are called the saddle part), a metal frame and artificial teeth. The basis is a part of the clasp prosthesis, bearing flase teeth, replacing part of the alveolar process. The dimensions of the basis depend on the size of the defect topography. In bounded defects, the bases are small, in free-end saddles –they completely overlap the alveolar process with maxillary prominences on the upper jaw, retromolar pads on the lower one.

The frame of a clasp prosthesis consists of connecting elements (arches and branches), fixing elements (clasps, interference and telescopic elements, bar retainers), stabilizing elements (continuous clasp, finger-shaped clasps) and unloading elements (shock absorbers and load crushers).

The arch connects the saddles of a clasp prosthesis and distributes the masticatory chewing pressure on the retainer teeth and the alveolar process. The location of the arch is determined by the size, topography of the defect, anatomical features of the hard palate, the alveolar process, attachment of the frenulums. The arch located on the upper jaw is called palatine, or palatinal. This is a plate having the thickness of 0.6 to 1 and the width of 5 to 15 mm. In a flat palate, poorly expressed alveolar processes, free-end edentulous spaces, the arc should be in the form of a wide and thin plate. The width is not less than 2 cm, and the thickness is 0.35-0.6 mm. This shape of the arch redistributes the masticatory load better. When the defect of the dentition is located in the frontal part, the arch passes in the anterior third of the palate to exclude overturning the prosthesis.

On the lower jaw, the arch is placed on the lingual side, in the middle of the alveolar process. It should be spaced away from the mucous membrane, so that at introducing the prosthesis in pliable tissues, it does not injure the mucous membrane and the lingual frenulum. However, the further the arc is spaced away from the alveolar part, the more it becomes palpable for the tongue. The arch of the prosthesis for the lower jaw has the shape of a half-ellipse measuring 4x2 mm. If soft tissues of the oral cavity floor are located high or lingual frenulum is present, an extended multi-section clamp can be used.

The arch can be provided with additional branches. They are directed towards the frontal defects and connect metal beds for fixing artificial teeth. These arches are thinner in size and worse than the main ones.

The stabilizing elements serve to prevent the displacement of the prosthesis in the horizontal direction and prevent lowering of the posterior edge of the upper jaw prosthesis in the presence of bilateral free-end edentulous spaces. As these elements, continuous and multi-section clamps and stabilizers are used.

### ***Clasp fixation.***

Currently, orthopedic dentists have various designs of clasps that enable to fix prostheses in difficult clinical conditions. The most common and effective system for fixing clasp prostheses is the system of molar denture clasps By Ney.

All existing varieties of clasps have both positive qualities and disadvantages.

Considering various types of clasps, it is possible to note common details in them: the shoulder, the body, the process of the clasp and the occlusal onlay.

The shoulder of the clasp is its springy part, covering the crown of the tooth. Its position is determined by the clinical contour height.

The body of the clamp is called its fixed part, located above the clinical contour height of the retainer tooth, on the contact side.

The process is intended for fixing the clasp in the frame of the clasp prosthesis.

The support-retaining clasps (molar clasps) have an occlusal onlay located on the occlusal surface of the tooth. With its help, the masticatory pressure is transmitted to the retainer tooth.

***Clinical and functional requirements for a natural tooth crown chosen for placing a support-retaining clamp.***

1. The tooth must be stable. In pathological mobility of the teeth, they should be blocked with neighbouring ones to form a stable system. Teeth with chronic periapical inflammatory foci can be used for support only after successful canal filling.
2. The teeth should have a pronounced anatomical shape. Teeth with a low cone-shaped crown, an exposed neck and a sharp violation in the ratio between the length of the clinical crown and the root are unsuitable for clasp fixation. These disadvantages are relative contraindications. After special preparation, such teeth can be included in the number of supports of the clasp system.
3. It is necessary to take into account the relationship of the supporting tooth with the opposing one. These relationships can be so close that even a small occlusal onlay placed in the fissure on the chewing surface will disrupt the occlusion. In such cases, another tooth should be chosen to place the support element, or a crown should be made on the retainer tooth.

***Ney system molar clasps, designs, indications for use;***

The Ney clasp system was developed in 1956 in Frankfurt am Main by a group of specialists, which included dentists, dental technicians and metallurgical engineers. Its authors took into account the fact that the fracture of the wire clasp always occurs at the place of its exit from the base, and proposed to make the clasp body and its upper part thick. This rigid part of the clasp, located above the boundary line, should cover the tooth by  $\frac{3}{4}$  of the crown. A certain position on the tooth, rigidity of this clasp part give the opportunity to counteract prosthesis lateral displacement.

Fixation of the prosthesis takes place due to the retention part of the clasp shoulder, which goes under the clinical contour height. The supporting and stabilizing function of a clasp prosthesis is provided by all elements located above the clinical contour height. The Ney system is

represented by 5 types of clasps. The first type is a rigid molar Acker clasp, it has one occlusal onlay and two shoulders. It is used in bounded leveling spaces and in cases when the line of sight divides the vestibular and oral surfaces of the tooth approximately in half. In this clasp, the retention function is performed only by the distal ends (1/3 of the shoulder length) of the vestibular and oral shoulders.

The second type is an elastic molar denture clasp, it has one occlusal onlay and two T – shaped split end sections of the shoulders (Roach clasps). It is used for free-end edentulous spaces of the dentition on the premolars. It is recommended to choose this clasp when the line of sight passes diagonally and when this line is located high (close to the occlusal surface).

The third type is a combined clasp, consisting of a rigid shoulder with an occlusal onlay (like an Acker clasp) and an elastic shoulder of Roach clamp. It is used at different levels of the line of sight location on the tooth surfaces. The rigid shoulder is located on the surface where the line of sight is located low (close to the gingival edge), the elastic shoulder is on the opposite side, where the line of sight is located close to the occlusal surface. The clasp is used on premolars, molars and canines.

The fourth type is a single-shoulder clasp of posterior (reverse) action, it has an occlusal onlay and one shoulder passing along the oral and vestibular surfaces of the tooth. It is used on premolars and canines, in free-end edentulous spaces of the dentition.

The fifth type is circular (annular), it is similar in design to the fourth type, is used on molars, has 1-2 occlusal onlays and one shoulder located on the oral and vestibular surfaces of the tooth. The end part of the circular arm is located close to the occlusal surface.

Improper fitting can result in a poor fit of the splint to the teeth and to a decrease in the therapeutic effect.

### ***The way of introducing and removing a clasp prosthesis;***

The way of introduction is the movement of the prosthesis from the initial contact of its clasp elements with the leveling teeth to the tissues of the prosthetic bed, after which the occlusal onlays are installed in their beds, and the base is precisely located on the surface of the prosthetic bed.

The way of removing the prosthesis is defined as its movement in the opposite direction.

The best way of introduction and removal is considered to be the one in which the prosthesis is easily applied and removed and at the same time provides the same retention on each tooth where there are retention elements. The way of introducing and removing the prosthesis is determined using parallelometry.

***LDS. Orthopedic treatment with clasp prostheses for partial adentia and parodontal diseases:***

***The components of a clasp prosthesis.***

Bases (correspond to the number of defects in the dentition). Frame (frame elements):

- ✓ transverse arch (bugel);
- ✓ grippers for saddles;
- ✓ load crushers, stabilizers.

***Clinical and laboratory stages of manufacturing bugel prostheses with a clasp fixation system:***

A solid-cast frame can be made using two methods. In the first case, the wax blank is removed from the working model and the frame is cast according to the technology of casting according to smelted models. In the second case, a copy of the working model is made from a special refractory mass, on which the casting process is performed. The second method is more labor-intensive, but it should be preferred, since it allows to avoid deformation of the wax blank when removed from the model, to eliminate shrinkage and deformation of the frame during casting and during metal cooling due to the thermal expansion coefficient of the refractory mass.

***Manufacturing solid-cast removable splints consists of the following stages:***

1. studying diagnostic models;
2. grinding areas of occlusal teeth surfaces to place occlusal parts of splints;
3. obtaining impressions and working models, determining the centric occlusion;
4. studying the working model in a parallelometer and the choice of the route of introducing a splint or a splint-prosthesis;

5. planning of the splint design and drawing of its frame on the plaster model;
6. preparing the model for duplication and obtaining a refractory model;
7. reproduction of the splint frame pattern on the refractory model;
8. modeling the splint frame;
9. creating a gating system;
10. applying a refractory coating, obtaining a casting mold, the casting process;
11. facing the splint frame;
12. checking the splint frame in the oral cavity;
13. final finishing and polishing of the splint ;
14. applying a splint to the dentition.

Stages 6-11 are performed by a dental technician, stage 5 – by a dentist or a dentist together with a dental technician.

After examining the patient, an approximate drawing of a removable splint is applied to the diagnostic models. The pattern of splinting elements (the clasp type) is chosen based on clinical data and the need not only to combine the teeth into a single block, but also to remove the traumatic effect of horizontal and vertical components of masticatory pressure affecting each tooth and functionally oriented groups of teeth. Having folded the models in the central occlusion, location of the occlusal onlays, post dams connecting the splint's oral and vestibular parts, the throw-over elements of the clamps is determined. If there is no space on the model, areas to be ground are marked with a red pencil. If a place for occlusive elements is not created, the latter will be very thin and will eventually break or disrupt the occlusion of the dentition.

The areas of cusps on the opposing teeth that are in contact with the zone where the throw-over element will pass are ground. Only in the case when this is not enough, the transition zone of the chewing teeth surfaces to the approximate one is ground. On the models, the zone of removing the cutting edges is marked when making a cast mouthguard for the frontal group of teeth. The enamel layer is ground along the planned areas and its size is controlled during occlusive movements of the lower jaw. The thickness of dams should be not less than 1 mm, the width – up to 1.5 mm. The longer the shoulder of the clasp is, the thicker is its occlusal

part. After stripping the teeth, impressions and working models are obtained.

When manufacturing a removable solid-cast splint, as well as a splinting clasp prosthesis, for unhindered application and preserving the splinting properties of all elements, it is necessary to determine the way of introducing and applying the splint on the dentition, zones for the stabilizing and retention parts of the clasps. The surface of the teeth crowns has the greatest perimeter. The line connecting the points of the largest perimeter on the tooth surfaces is called the anatomical contour height, which as if divides the crown into occlusal and gingival parts. The anatomical contour height coincides with the greatest convexity of the tooth only in cases of vertical location of the longitudinal axis of the tooth crown. In the clinical practice, due to teeth inclination, the line of the anatomical contour height does not coincide with the greatest tooth convexity in relation to the vertical plane, that is why they often talk about the clinical contour height of the tooth. If the tooth is inclined orally, the line of the clinical contour height from the lingual side shifts to the occlusal surface, and from the vestibular side it descends to the gingival margin. A similar position is observed in this or that inclination of the model. Inclining the model, it is possible to change the axis of the tooth inclination, and therefore, the location of the largest convexity in relation to the vertical plane.

Having considered the issue of changing the clinical contour height, it is necessary to stop at determining the general clinical contour height line of the dentition, or, as it is also called, the line-of-sight, the general contour height line.

After drawing the contour height line, a drawing of the frame of the clasp prosthesis is applied. The position of the lower edge on the clasp arm retention part is determined using a pin-meter of the retention degree. For chromium-cobalt alloys in case if the thickness of the clasp arm is equal to the thickness of standard wax blanks, it is better to use the retention of 0.5 mm.

After parallelometry, drawing the frame of the prosthesis and obtaining grooves indicating the location of the lower edge on the clasp shoulder retention part, a layer of refractory wax is applied to all parts of the working model that have undercuts. Then, in the parallelometer, the excess is smoothed with a pin knife in all areas to a vertical cylindrical

surface. Such preparation of the model prevents detachment of the duplicate mass when removing the gypsum working model from it. An additional wax layer should not cross the drawing of the frame contours and applied grooves.

The prepared model is immersed for 2-3 minutes in water and a refractory model is obtained as follows.

The working model is placed on the pallet of the flask for duplication and, if there are gaps, they are closed with any plastic material (moldin, plasticine). The pallet is covered with a flask having 2-3 holes at the flat end. Preliminarily, in a special device or in a vessel over a pan of simmering water, the hydrocolloid mass is heated, stirring constantly. The readiness of the mass is judged by its consistency and homogeneity: the mass should have no lumps, and its temperature should not exceed 55-60°C. At a mass temperature of 38-45°C, it is poured into a flask through one of the holes on the end. The mass becomes hard in the air for 30-45 minutes, turning into a durable elastic gel. After that, it is necessary to place the flask under a stream of cold water for 15-20 minutes, so that the inner layers of the mass solidify. After removing the tray of the flask, a gypsum working model is removed from the mass. The shape obtained from the hydrocolloid mass is the exact shape for the refractory working model. From the side of the removed pallet, a standard cone is inserted into the center of the hydrocolloid mass cast and filled with a refractory mass (“Silamin”, “Christosil-2”).

These masses are prepared in accordance with the instructions. They have a small percentage of expansion during solidification (0.2%) and thermal expansion (not less than 0.8% at a temperature of 500-700°C). Together with the volumetric expansion of the die stone during solidification, this compensates for the metal shrinkage during its curing. After the refractory mass curing, a duplicate mold is squeezed out of the flask through the filling holes. The refractory model is released from the mass using layer-by-layer cutting.

All refractory models require special thermochemical treatment. Heat treatment at the temperature of 120-160°C is carried out for 30-40 minutes in a drying cabinet, preheated to 40°C. The dried non-cooled model is placed in a molten (150°S) fixative for 30-60 seconds to give durability and smoothness to the surface layers of the model.

A drawing of the frame is applied to the refractory model prepared in this way, being oriented by the drawing on the working plaster model, and the lower boundaries of the retention part are determined by the notches. Then, according to a well-known technique, the wax composition of the prosthesis is modeled. The gating system is created from wax arch-shaped curved blanks fed to the thickest sections. The gating pins are come down to the hole available in the model, formed when it is cast with a standard cone. This is followed by the process of applying a facing layer of the mold to the frame, forming the model, casting and finishing the frame.

The casting process includes a number of sequential operations:

1. producing wax models of parts (when casting on refractory models, preliminary obtaining them);
2. installing gate-forming pins and creating a gate system;
3. coating models with a refractory facing layer;
4. forming a model with a refractory mass in a muffle;
5. wax melting;
6. drying and firing the mold;
7. alloy melting;
8. alloy casting;
9. release of parts from the refractory mass and the gate system.

When casting denture parts, the most important *thing is* to combat shrinkage of alloys and wax compositions. All intermediate operations, reduction of wax compositions shrinkage, creation of special compensating molding masses, the system and nature of sprues and methods of melting alloys are subordinate to this. All wax compositions, as well as metal alloys, passing from a liquid state to a solid state, give the following shrinkage: wax compositions-0.5-2%, stainless steel— 1,1-1,25% (1,2-2,2% in thick-walled products), gold alloys-1.25% (in gold and platinum alloys the value is slightly less), silver-palladium alloys-up to 2%. Shrinkage of wax compositions is reduced by creating mixtures of waxes, as well as by modeling parts not from a molten, but from a softened mixture. The shrinkage of alloys is compensated with the help of special compensating molding masses, which have a double coefficient of expansion: expansion during solidification (0.8-1%) and thermal expansion characteristic of all bodies when heated (0.6-0.75%). The more it is possible to balance the percentage of shrinkage of wax mixtures and

metal alloys by expanding the molding masses, the more accurate and better casting is obtained.

Obtaining wax models of dental prosthetic parts is described in special sections of the textbook, since modeling is specific to various prosthesis designs. The casting process is described in a strict sequence, with an explanation of all manipulations and means used to compensate for the shrinkage of alloys. For all methods of casting in a casting mold, except for the form of a metal casting, a gating system is also provided, which represents channels through which liquid metal is supplied to the casting. The gating system is created by feeding the gating pins to the wax part. These pins can be metal and wax. The construction of a gating system in precise casting according to smelted models is determined by the following principles:

1. all parts of the casting must be in equal conditions during casting;
2. all thick-walled sections of the casting must have an additional depot of liquid metal to eliminate shrinkage shell, friability and porosity in the metal;
3. the hottest metal should be brought to the thin sections of the castings. Experiments have shown that not only the length and diameter of the casting channel, but also its direction and location are of great importance for obtaining high-quality casting. The direction of the casting channels should correspond to the direction of the hollow space, so that the molten metal does not change its direction sharply, and the centrifugal force used during casting contributes to the metal compaction;
4. the molten metal should flow from thick-walled areas to thin-walled ones. If the part has several thick-walled sections connected by means of thin-walled sections, then each thick-walled section should have its own casting channel (sprue-forming pin).

The thickness of the sprue-forming pin should be not less than 1.5 mm, even for small casting parts. The thicker the part is or the greater is its length, the greater the number of sprues of a larger diameter should be brought to it. It is not recommended to take a sprue-forming pin with a diameter of more than 3-4 mm, since there may be a danger that the molten metal under the influence of gravity will enter a wide channel even before centrifugation and clog it. When receiving a large part (a

solid-cast prosthetic bridge or clasp prosthesis), one central casting material channel is installed, which is then divided into smaller ones that are supplied to the three-dimensional prosthetic parts. If the part has a small length, then it is possible to enter 2 or 3 metal pins, crossing them at one point. If a part of a complex configuration having different thickness along the length (the frames of the clasp prostheses) is cast, then not straight, but somewhat curved wax sprue-forming pins are installed. This arrangement of sprues prevents deformation of the cast part when metal solidifies and the flask cools.

The quality of the parts can suffer greatly due to shrinkage cavities formation. The molded metal begins to harden from the outer layers, and for some time the cast surface represents a solid crust, under which there is a liquid metal. Naturally, the metal residue located above the surface of the mold hardens earlier. Shrinking when cooling, it draws in a particle of molten metal located in the depth of the flask, or, decreasing in volume, it does not fill the entire space of the mold. To avoid the formation of shrinkage cavities and to reduce the degree of a part's shrinkage, a metal depot outside the part are created, the so-called couplings. Shrinkage cavities are moved into these couplings, since the latter are a reservoir of molten metal for longer time, and the solidifying product, as well as the metal residue on the surface, seem to draw liquid metal into themselves from the coupling. At this, of course, solidification sequence should be provided: first the product, and then the coupling.

An important role in this case is played by a correct mode of the mold heating before casting. Shrinkage is compensated with the help of the coupling,. Further cooling, the casting draws the uncured metal out of the coupling, and thus the shrinkage as if moves into the coupling.

To avoid under-watering, when plastering, the distance between the part and the bottom of the flask should be about 0.8-1.2 cm. A coupling must be applied to each sprue-forming pin. To avoid underflows when casting thin-walled parts or parts having a large length and different thickness, it is necessary to introduce bypass canals for air into the gating system.

After installing the gating system, a casting mold is started to be created .

***Manufacturing the facing layer for the casting mold.*** Casting molds are made from molding mixtures, which include gypsum,

refractory and binding substances or special refractory masses. The mixture must have the following properties: it must be plastic, strong, gas-permeable and fire-resisting, it must not expand when solidified and heated. Forms in precise casting are made two-layered. The inner layer of the mold, called the facing layer, is directly in contact with the molten metal and therefore must be highly refractory, durable and gas permeable. The facing layer forms the geometric dimensions of the casting, so it is necessary that it accurately copies the model. If the facing layer is not strong, the jet of molten metal can destroy it and block the access of the metal to other parts of the mold or distort the contours of the cast part. In low refractory property of the mold's facing layer, it can melt under the influence of high temperature of the metal. The surface of the cast part will become uneven after cleaning, and the cleaning operation will be difficult, since the particles of the facing layer of the mold will fuse with the metal. The purpose of the outer part of the mold is to strengthen the facing layer. However, the outer part of the mold must also be gas-permeable, sufficiently strong and refractory. All facing materials in precision casting according to smelted models consist of a filler powder and a liquid (gluing, binding substance).

Refractory materials are used as a filler for the facing layer of the mold, they represent a fine powder:

- marshallit (fine grinding of natural quartzite or pure quartz sand)  
– fire resistance 1700° S;
- corundum (aluminum oxide);
- electrolytically produced corundum;
- fused quartz.

The use of quartzites as fillers is based not only on their high fire resistance, but also on their property of giving residual changes in volume when heated. In prolonged heating, quartzite passes into other modifications, increasing in volume by 15-19%. By mixing quartzites with gypsum, it is possible to get a mass with the necessary coefficient of expansion. All these materials do not have plasticity. That is why, binding substances are introduced into the composition of the facing masses — high-molecular siliceous compounds (ethyl silicate, liquid glass). To obtain a binder based on ethyl silicate, it is subjected to hydrolysis. As a result of reactions going in several phases, formation of polymer molecules occurs. For hydrolysis, 10 parts of ethyl silicate are

taken for 1 part of water. To prevent the formation of a gel, pure 92-96% ethyl alcohol is used, diluted with an estimated amount of water.

Due to the fact that wax models have low strength, and casting molds are integral in order to increase the accuracy of casting, the only way to apply a facing layer to the model *is* to cover the models with a refractory liquid, which after drying and heat treatment becomes sufficiently strong and refractory.

The coating process is as follows. The technician takes a model or a block of wax models by hand for the GATING SYSTEM and plunges it into a vessel with a prepared mixture of a filler and a binder. To apply the first layer, the block is immersed in the mixture 3-6 times. After the last immersion, the excess mixture is allowed to drain from the block, for which it is rotated over the vessel. It is necessary to ensure that the mixture evenly covers all parts of the details and does not form thickened layers. The mixture can be applied with a soft hair brush, first covering the deep-lying areas of the models.

As soon as the excess mass flows off the models, it is necessary to quickly and carefully dust the model with dry quartz sand in order to fix the applied facing and prevent it from draining from individual sections. Drying of the facing layer of the coating is carried out on special stands at the temperature of 20°C for 1-2 hours and under a slightly heated air jet for 40-50 minutes. Preparation for molding and molding itself are carried out in the following order:

1. installation of facing models on the flask cone;
2. selection of the casting flask (casting-box);
3. strengthening the flask on the cone;
4. filling with molding mixtures.

The shape of the cone plays an important role in the casting process. The size of the cone determines the size of the formed funnel in which the metal melts. When heated, a crack may appear in the facing layer. To prevent this, before molding, the flask is covered with several layers of parchment paper, which serves as a compensator, from the inside. At a high temperature, it burns, and the molding mass has the ability to freely expand to the thickness of the paper layer (0.3 mm). The molding mass is a mixture of river sand with boric acid (90 parts of sand and 10 parts of boric acid), gypsum in a ratio of 1:1, a mixture of gypsum and sand.

Wax melting should be carried out in muffle furnaces at the temperature of 40-60°C, which is slowly increased within half an hour to 100 – 150°C. At this, the wax melts and flows out (the flask must be installed with the gate holes down or obliquely). The wax melts under the influence of heat, flows out of the mold and floats to the water surface. The molds are dried in the air for 20-30 minutes.

***Drying and firing the mold;*** The mold contains moisture, that is why the firing process is preceded by drying. Drying should be carried out slowly (to avoid the formation of a large amount of steam) at a temperature of 100°C. Then the temperature of the muffle furnace is gradually brought up to 800-850°C during 2 hours and the mold is fired. Firing is necessary to burn out the wax residues, to increase gas permeability of the mold, to obtain the necessary thermal expansion and to create a high temperature inside the mold and the gating system for better metal fluidity and filling of thin-walled sections of the mold.

Alloys used in orthopedic dentistry are divided into three groups depending on the melting point. The first group consists of alloys with a melting point of up to 300°C (low-melting alloy based on tin, tin with silver and copper additive, etc.)/ the second – alloys with a melting point of up to 1100°C (gold, silver-palladium alloys). The third group includes alloys with a melting point above 1200°C (stainless steel, chromium-cobalt alloys, etc.). For melting alloys of the second and third groups, special equipment is required that allows reaching a high temperature. Casting is carried out in high-frequency furnaces. The essence of the method of induction heating by high-frequency currents is that the molten metal is placed in the electromagnetic high-frequency field of the inductor. In this case, alternating currents are induced in the metal ingot, the so-called high-frequency eddy currents. Due to high density of the induced currents on the ingot surface, the metal is rapidly heated and melted. High-frequency currents include alternating currents with a frequency of 500 to 10000000 Hz (an ordinary current of the city network has a frequency of 50 Hz). High-frequency currents are obtained from high-frequency generators.

In order for the metal to fill the mold cavity formed after wax melting, pressure on the metal should be created. Depending on the nature of the resulting pressure on the metal, the following casting

methods are distinguished: a) pressure casting; b) centrifugal casting; c) vacuum casting.

Pressure casting and centrifugal casting are based on creating pressure on the metal from the outside. In this casting, more dense castings are obtained, it eliminates porosity, under-casting, shrinkage cavities. Centrifugal casting has become widespread.

There are many systems of casting machines using the action of centrifugal force. There is an automatic centrifuge for casting denture parts. Vacuum casting is based on creating a negative pressure inside the mold. This helps to remove gas bubbles from the mold cavity, which prevents the formation of pores, but at the same time less compacted castings are obtained.

Processing of cast metal parts. After the casting process, the flask is cooled in air, parts of different thickness along their length and large parts (the frame of a clasp prosthesis) are placed in heated muffle furnaces and cooled together with it. Then the molding mass is carefully removed with a plaster knife and release the cast parts from it. Then processing the cast part starts. Processing is necessary if irregularities, roughness, and excess metal are found on the surface. The processing begins with the removal of the sprues. For steel and chrome-cobalt parts, it is produced on the motor with a carborundum disk. Due to high hardness of these alloys, further processing is carried out first with a sandblaster, and then with the help of carborundum stones and metal burs. By processing with stones and burs, a flat surface is obtained. If there are under-spills and cavities in the casting, the processing is stopped and the wax part is modeled again.

## ***Lesson №10***

---

***Training subject*** “Orthopedic treatment of partial adentia with clasp prostheses with a telescopic, interference and bar fixation system”.

***The purpose of the lesson:*** study of indications and design features of supporting removable prostheses with a telescopic, interference and bar fixation system.

***Practical lesson plan:***

1. Checking the initial level of knowledge;
2. Explaining the next clinical material with the demonstration of thematic patients.
3. Independent students' work on the theme of the practical lesson.
4. Generalizing the lesson's content with ongoing monitoring the retention of the lesson materials.
5. Homework with a recommendation of educational literature.

***Control of the initial level of knowledge:***

1. Types of removable palatal dentures.
2. Indications and contraindications for manufacturing palatal dentures.
3. What is the "parodontal reserve forces":
  - ✓ parodontium of a non-fixing group of teeth;
  - ✓ manifestation of the periodonto-muscular reflex;
  - ✓ the strength acquired by periodontal training;
  - ✓ the ability of the parodontium to adapt to the changed masticatory load.

***Control questions on the topic of the lesson:***

1. Advantages of resting removable palatal dentures over submersible prostheses.
2. Bar prostheses with a telescopic attachment.
3. Interference fixation. Types. Purpose. Structural elements. Advantages and disadvantages.
4. Bar attachment. Purpose. Structural elements. Advantages and disadvantages.

***Lesson content:***

***Telescopic attachment.*** This type of attachment consists of two parts – internal and external. The inner part is represented by a metal cap covering the tooth pulp. The outer part is a crown with a pronounced anatomical shape. The inner part is strengthened on the tooth with cement, the outer part is connected to the prosthesis. According to the principle of transferring masticatory pressure to the supporting teeth, telescopic crowns should be attributed to non-clasp attachment systems.

***Interference fixation and hinged attachment.*** Mechanical devices for fastening parts of a dental prosthesis are called attachments (from the English *attachement* — attachment). Interference and joint (hinged) attachments are distinguished. All existing attachments are divided into two classes: intradental and extradental. The first class includes the largest number of attachments. Their name implies that they are partially located in the crown or the root of a natural tooth. The second class includes cantilever and bar devices. Cantilever ones can be rigid and movable, in their turn, movable ones are divided into rotating and elastic, which are called hinges.

Each attachment consists of two main parts — the patrix (internal) and the matrix (external). Depending on the design of the clip, a patrix or a matrix can be fixed in the prosthetic base. The rule is the need to fix the most complex, activated part of the attachment in the removable prosthesis, since it goes out of service earlier, and it is necessary to provide for the possibility of easy correction, and if necessary, replacement without complete re-manufacturing of the prosthesis.

The sequence of clinical and laboratory stages in manufacturing removable prostheses with fixing elements in the form of attachments includes:

- ✓ production of non-removable prostheses with the dental part of the attachment;
- ✓ obtaining impressions of the jaws together with non-fixed non-removable prostheses;
- ✓ manufacturing working models with non-removable prostheses with interference fixation;
- ✓ determination of centric occlusion and installation of models in the articulator;
- ✓ modeling, manufacturing, fitting on models of removable prostheses with attachments;
- ✓ fitting and fixing non-removable prostheses with simultaneous application of removable prostheses.

It should be emphasized that the installation of interference fixations in non-removable prostheses is necessarily carried out in a parallelometer.

All interference fixations, as a rule, ensure the prosthesis mobility in the vertical direction, which allows to freely apply and remove it.

There is a significant difference between the action of the clasp and an interference fixation. The clasp does not have an active force at rest, it is under pressure only the prostheses move; a somewhat different situation is formed in interference fixations. To create friction forces, one of the outer parts must always be in a tension state. This leads to the material rapid wearing off and breakage of the interference fixation.

**Bar attachments.** Bar attachments are used for prosthetics of bounded leveling spaces. This design includes a non-removable support part in the form of crowns or over-root caps, between which there is a bar or a beam; respectively, a metal counter-bar is located in the base, exactly repeating the shape of the bar. A Rumpel bar is rectangular flat, and a Dolder bar is tear-shaped, due to which there is a reliable stabilization and fixation of the prosthesis through the corresponding counter — bar, which has only one degree of movement freedom — vertical, coinciding with the axis of the retainer teeth. The use of this design is recommended for the rectilinear shape of the alveolar ridge. In an arc-shaped ridge through the bar on the retainer teeth, when biting or chewing food, a lever-shaped inclining moment takes place, which negatively affects the condition of the parodontium. The retainer teeth in a Rumpel system should be high enough to position the bar without reaching the mucous membrane by 1.5-2 mm.

The Dolder system is indicated mainly for manufacturing prostheses for the lower jaw. Having a spherical congruent surface, the base under the action of chewing pressure and pliability of the mucous membrane performs a rotational movement around the axis of the bar, without creating negative lateral loads on the parodontium of retainer teeth.

The production of a clasp prosthesis begins with obtaining an impression from the jaw and casting diagnostic models.

When manufacturing clasp prostheses impressions from the jaws are removed with an alginate mass.

On the diagnostic model, preliminary planning of the clasp prosthesis frame is performed.

Removable clasp (supported) prostheses distribute the masticatory load more favorably between the retainer teeth and the mucous membrane of the alveolar ridges and the palate than plate (submersible )

ones, which allows to increase their functional value, to reduce the boundaries of the prosthetic bed and to improve the conditions for using the prosthesis.

Structures with a telescopic attachment are noteworthy. A telescopic (double) crown consists of an external and an internal part. The outer crown has an anatomical shape and moves upon the inner one (the shape of a telescope). The inner crown should be cylindrical.

The preparation of the tooth is the same as in manufacturing a simple cast crown. The processed tooth stump is given a cylindrical or slightly conical shape. On the chewing and approximal surfaces, the tooth is processed a little more than in manufacturing a solid-cast crown, in order to get enough space for a telescopic (double) crown, without violating the occlusion and physiological conditions in the interdental space. The outer crown may be 0.5 mm shorter than the inner one. Properly modeled telescopic crowns easily fit on top of each other. The telescopic system gives the opportunity to get a rational attachment of the prosthesis to the retainer teeth, it gives a strong and rational support that covers the tooth in an annular manner. That is why this design can also be recommended for loose teeth. Functional load is beneficial and can lead to tooth imbedding. If the external telescopic crown is made as an anatomical one with a porcelain or plastic facing, then the aesthetic result is quite good.

The telescopic system gives a better attachment of the prosthesis than the clasps, if correct indications for its use are observed. Various types of spring attachment can be attached to the telescopic system, since there is enough space for this. The telescopic system can be used when there are several retainer teeth and when only one is left.

Interference fixation consists of two elements that are inserted into each other, into the grooves. The part that is fixed on the retainer tooth on inlays, crowns, is called the matrix (the negative part of the clip), and the inner part connected to the prosthesis is called the matrix (the positive part of the clip).

There are many such constructions, it is impossible to list them all. The most famous by the section shape are a ball clip, a cylindrical clip, an oval clip.

For dental parodontium, the forces of tipping and rotation of the prosthesis are harmful. Clips can be used as guiding support elements and

as retaining ones. The guiding retainer implies that the clip, when installed in the prosthesis, gives it only a certain direction. Any interference fixation can be used as a holding support element when small prostheses are included. However, it should not be forgotten that horizontal forces because of short and rigid clip shoulders are transferred to the retainer teeth. On prostheses that replace free-end edentulous spaces, all clip designs give a rigid connection of the prosthesis with the retainer tooth, with the exception of a wide lock, the location of which on the upper jaw is ineffective.

The purpose of using clips is to eliminate attachment with clasps for aesthetic and hygienic reasons. However, they are more expensive and represent more sensitive structures. Their processing is also difficult.

Now such devices are used in the form of precision clips. The cemented inlay in the crown is the clip matrix and is complemented by a removable matrix. In this case, the “closing” is performed only in order to install the matrix in place.

According to their function, the matrix and the matrix form a rigid fixed element and give the clip the same size as the crown support.

The precision clip is different from the old devices. If earlier a clip was installed on the side of the artificial crown or was introduced inside, now the metal crown is performed as a precision clip. The name “grooved shoulder pin lock” contains three main structural elements: the groove is a guiding element, the shoulder serves for vertical movement and the transfer of masticatory pressure to the retainer tooth.

Clips require very precise manufacturing in the laboratory and imply the need to use a parallelometer. Clips have the aesthetic advantage of invisibility, since they are installed inside the crown. The difficulty of replacing an interference fixation makes the scope of their application limited.

The bar attachment is characterized by the fact that the crowns on the retainer teeth are connected by cast round or four-sided bars, which, with the help of a removable prosthesis, perceive the masticatory pressure. Thus, a supporting frame is created through which the masticatory pressure is distributed on the surface of the alveolar ridge and the teeth, not overloading them. The retainer teeth are protected from the action of horizontal components of the masticatory pressure by the features of this attachment. The connection of the retainer teeth with a bar

can be applied both in the area of anterior and in the area of lateral teeth (bounded defects).

A half-shell is welded into the saddle of the arc prosthesis, exactly repeating the external contours of the bar on which it will rest. The pressure of the prosthesis is transmitted to the bar and to a small extent to the mucous membrane of the alveolar process. This system was developed by Schroeder and Rumpel. Dolder suggested using clamps made of elastic metal that snap on the bar when the prosthesis is applied. Thus, when using beams, 2 prostheses are made (removable and non-removable), which must correspond to each other.

The use of bar eveling is possible when the retainer teeth have high clinical crowns. When the crown part height is low, there is no room for the base of the prosthesis and artificial teeth, and a small soldering area does not provide the proper strength of the bar with the retainer teeth.

## ***Lesson №11***

---

***Training subject:*** “Parallelometry (studying jaw models in a parallelometer)”.

***The purpose of the lesson:*** to teach students to choose correctly the design of the clasp prosthesis using parallelometry.

### ***Practical lesson plan:***

1. Checking the initial level of knowledge;
2. Explaining the next clinical material with the demonstration of thematic patients.
3. Independent students’ work on the theme of the practical lesson.
4. Generalizing the lesson’s content with ongoing monitoring the retention of the lesson materials.
5. Homework with a recommendation of educational literature.

### ***Control of the initial level of knowledge:***

1. The concept of “anatomical and clinical contour height of the tooth”.
2. The components of a clasp prosthesis.

3. Molar denture clasps of Ney system.

***Control questions to evaluate assimilation of the material studied:***

1. The purpose of diagnostic models.
2. In which cases do the anatomical and clinical contour heights coincide?
3. How are the parts of a support-retaining clasp located in relation to the line of the clinical contour height?
4. Advantages and disadvantages of the Novak method and the “logical” method.
5. Definition of the concept of “prosthetic contour height” (line of sight, boundary line, general equatorial line), change of its topography depending on the position of the model’s dentition in relation to the diagnostic pin.
6. A parallelometer. The main structural elements. Principles of operation.
7. Methods of parallelometry.

***Lesson content:***

Planning of a clasp prosthesis design consists in:

1. determining the way of introducing and removing a clasp prosthesis;
2. marking of the model to find the most convenient location of the clinical contour height on the retainer teeth and the corresponding position of the clasps/
3. determining the position of the arch on the palate and the alveolar process of the lower jaw and other elements of the prosthesis (multi-link clasps, branches, processes, etc.)

All this in general makes it possible to apply a drawing of the frame of the future prosthesis to the model. There may be three or four clasps (or more) in the clasp prosthesis that make up the clasp system. All supporting and retaining clasps, their elements should be located strictly in accordance with the clinical contour height – the largest perimeter of the tooth, taking into account its inclination. The clinical contour height coincides with the anatomical contour height only when the longitudinal tooth axis is strictly vertical. Usually, due to the physiological inclination of the teeth, the line of the anatomical contour height does not coincide

with the clinical one. If the tooth is inclined orally, the line of the clinical contour height from the lingual side shifts to the occlusal surface, and on the vestibular side it descends to the gingival margin.

For correct construction of clasps, it is important to determine the general clinical contour height line of the dentition, which is also called the clinical contour height, the prosthetic contour height, the contour height (Kennedy), the guiding line (Gumer), the boundary line (separation line) (E. I. Gavrilov), a general panoramic line.

The general panoramic line, or clinical contour height, divides the tooth surfaces into two parts: the supporting (occlusal) and the retaining (retention, gingival).

The position of the general panoramic line changes depending on the natural inclination of the tooth, as well as on the position given to the model in the parallelometer.

A common panoramic line for all the retainer teeth, in relation to which the elements of the molar denture clasp will be located, is determined using a special device — a parallelometer. A parallelometer is a device for determining the greatest convexity of teeth on models of jaws, identifying a relative parallelism of the surfaces in two or more teeth or other parts of the jaw, for example, the alveolar process.

The device has a flat base on which a stand with a bracket is fixed at a right angle. The bracket is movable in the vertical and horizontal directions. The arm of the bracket corresponds to the rack at an angle of 90°. There is a clamping device for replaceable tools on the arm of the bracket. This device makes it possible to move the tools vertically. The set of tools includes: a flat analyzer to determine the most favorable position of the general panoramic line, and consequently, the position of the clasps, which ensure an unobstructed introduction of the prosthesis and its good fixation; a pin in which slates for delineating the line are fixed with a collet; pins-meters of retention degree #1, 2 and 3; pins-knives for removing excess wax after filling the undercuts. The kit also includes a table for fixing models. The platform of the table is pivotally connected to the base, which makes it possible to incline the models and bring them to the tools at different angles.

All parallelometer designs are based on the same principle: at any displacement, the vertical rod is always parallel to its original position.

This gives the opportunity to find points on the teeth located on parallel vertical planes.

The size of the supporting-stabilizing and retention zones on the tooth depends on the position of the general line of view, or the clinical contour height, which, in turn, depends on the inclination of the model during parallelometry.

There are three known methods for identifying the way of prosthesis introduction:

1. random method;
2. method for determining the average slope of retainer teeth longitudinal axes (Novak's method);
3. method of tilting the model (selection method, or "logical" method).

**Random method.** The model, cast from high-strength gypsum, is installed on the parallelometer table so that the occlusal plane of the teeth is perpendicular to the pencil rod. Then, a parallelometer lead is brought to each retainer tooth and a general panoramic line, or clinical contour height, is drawn. In this method of parallelometry the line may not coincide with the anatomical contour height, since its position will depend on the natural tooth inclination, therefore, on individual teeth, the conditions for clasps placing may be less favorable. This method of parallelometry is indicated only when the vertical axes of the teeth are parallel, they are insignificantly inclined and have a minimum number of clasps.

**A method for detecting the average slope and the length of retainer teeth' axes.** The faces of the model's socle are cut off so that they are parallel to each other. The model is fixed on the parallelometer table, after which the vertical axis of one of the retainer teeth is found. The table with the model is installed so that the analyzing rod of the parallelometer coincides with the long axis of the tooth. The direction of the latter is drawn on the lateral surface of the model's socle. Next, the vertical axis of the second retainer tooth is determined, located on the same side of the dental arch, and also transferred to the lateral surface of the model. Then the obtained lines are connected by parallel horizontal lines, after dividing the horizontal lines in half, the average approximate axis of the retainer teeth is obtained. In the same way, the average axes of

the teeth on the other side of the model are determined. The obtained average axes are transferred to the free face of the model socle using the analyzing rod of the parallelometer, and the average axis of all the supporting teeth is determined by them. Then the table with the model is finally installed in the parallelometer. The analytical rod is changed to graphite one and a panoramic line is outlined on each support tooth. When drawing, the end of the graphite rod should be located at the level of the tooth neck. The disadvantage of the method is duration, difficulty and probability of error in determining the general panoramic line.

***The selection method.*** The model is fixed on the parallelometer table. Then the table is installed so that the occlusal surface of the model's teeth is perpendicular to the analyzing rod (zero slope). The latter is brought to each retainer tooth in turn and the presence and size of the supporting-stabilizing and retaining zones are determined. It may turn out that on one or several teeth there are good conditions for placing clasp elements, and on others they are unsatisfactory. Then the model should be viewed from a different angle of inclination. From several possible inclinations, the one that provides the best holding zone on all the retainer teeth is chosen. There are four main types of model inclination: front, rear, right lateral and left lateral.

When designing a clasp prosthesis, this method allows taking into account the requirements of aesthetics and the optimal degree of clasps retention. So, if the support-retaining clasps need to be placed on a group of teeth visible when smiling, then for aesthetic reasons it is advisable to bring the line of sight as close as possible to the necks of the retainer teeth. To do this, the rear inclination of the model is used, that is, the model is inclined backwards. The lateral inclination of the model is chosen for an even distribution of the retention degree on the leveling teeth of both halves of the jaw.

So, for example, if, when the model is horizontal, it turns out that the line of sight on the left lateral teeth is located in the buccal surface along the necks of the teeth (due to lingual teeth inclination), it is advisable to incline the model to the left in order to "raise" the panoramic line. The degree of lateral inclination of the model is determined by the sufficiency of the retention zone on the right lateral teeth.

Having fixed the movable table and the model placed on it in the chosen position, a general panoramic line is applied with a vertical pin with a pencil.

Bringing the pencil to each tooth so that its lower edge is located and moves along the level of the gingival edge, a line is drawn on the vestibular, oral and proximal surfaces of all teeth. After removing the model with the table from the parallelometer stand, a thin felt-tip pen or a soft pencil is used to circle the resulting general contour height line and proceed to planning the clasps design and drawing a picture of the future frame of the prosthesis splint.

The general clinical contour height is crossed only by the clasps retention parts. To determine the retention part location in the parallelometer, there is a special rod with a ledge – a retention degree meter #1, 2 and 3. The rod is secured in the shoulder of the parallelometer and set it so that it touches the clinical contour height. At this moment the ledge of the rod touches the point of the tooth below the clinical contour height. After passing the rod over the tooth, a notch is obtained that indicates the line of the retention part: at the 1<sup>st</sup> degree of retention — 0.25 mm below the clinical contour height, at the 2<sup>nd</sup> – 0.5 mm and at the 3<sup>rd</sup> – 0.75 mm.

The location of the clinical contour height line on the crown after parallelometry, its relation to the occlusal and gingival parts of the crown determine the need to choose one or another type of support-retaining clasp for each tooth. The choice of a clasp type depends on the topography of the clinical contour height and the area of the occlusal and gingival parts.

Taking impressions in clasp prostheses manufacturing is carried out according to the generally accepted method. It is necessary to carefully select the impression material and the size of the impression spoon. The choice of the impression material is influenced by the state of the mucous membrane of the prosthetic bed. The quality of the working model is of great importance, the doctor must constantly monitor its quality at all clinical stages: when determining the central occlusion, checking the design of the removable prosthesis. If defects in the working model are detected, the work should be suspended and the impression should be taken once more. To prevent such a complication, we recommend making working models from die stone.

# *Appendix 1.*

---

## CLINICAL RECOMMENDATIONS (TREATMENT PROTOCOLS) IN DIAGNOSED PARODONTITIS)

Approved by the Decision of the Council of the Public Organisations Association “Russian Dental Association” on April 23, 2013 with amendments and additions on the basis of Resolution № 15 of the Council of the Public Organisations Association “Russian Dental Association” dated September 30, 2014.

### I. APPLICABLE SCOPE

The clinical recommendations (treatment protocols) “Parodontitis” are intended for use in the healthcare system of the Russian Federation.

### II. REGULATORY REFERENCES

These Clinical Recommendations use references to the following documents:

. Resolution of the Government of the Russian Federation №1387 dated 05.11.97 “On measures for the stabilization and development of healthcare and medical science in the Russian Federation “(Collection of Legislation of the Russian Federation, 1997, №46, Article 5312).

. Order of the Russian Ministry of Health and Social Development №1664n dated December 27, 2011. On approval of medical services nomenclature.

. Federal Law №323-FZ dated November 21, 2011 “On the basics of protecting the health of citizens in the Russian Federation “(Collection of Legislation of the Russian Federation, 2011, №48, Article 6724).

### III. SYMBOLS AND ABBREVIATIONS

The following symbols and abbreviations are used in these Clinical Recommendations:

ICD-10-International Statistical Classification of Diseases and Health-Related Problems  
of the World Health Organization in the tenth revision.

ICD-C is an international classification of dental diseases based on ICD-10.

#### IV. GENERAL PROVISIONS

The clinical recommendations (treatment protocols) of “Parodontitis” are designed to solve the following tasks:

- establishment of uniform requirements for the procedure of diagnosis and treatment of patients with periodontitis;
- unification in the development of basic programs of compulsory medical insurance and optimization of medical care for patients with parodontitis;
- ensuring the optimal volume, availability and quality of medical care provided to the patient in a medical institution.

The area of distribution of these Clinical Recommendations is dental medical organizations. These Clinical Guidelines use a scale of evidence-based persuasiveness.:

- A) The evidence is convincing: there is strong evidence for the proposed statement.
- B) Relative strength of evidence: there is sufficient evidence in favor in order to recommend this offer.
- C) There is no sufficient evidence: the available evidence is not sufficient to make a recommendation, but recommendations can be made taking into account other circumstances.
- D) There is enough negative evidence: there is enough evidence to recommend against the use of this drug, material, method, technology in certain conditions.
- E) Strong negative evidence: there is sufficient conclusive evidence to exclude the drug, method, methodology from recommendations.

#### V. MANAGMENT OF CLINICAL RECOMMENDATIONS (TREATMENT PROTOCOLS)

Management of clinical recommendations (treatment protocols) “Parodontitis” is carried out by the Moscow State Medical and Dental University named after A. I. Evdokimov under the Russian under the Ministry of Health of the Russian Federation (A. I. Evdokimov MGMSU under the Russian under the Ministry of Health of the Russian

Federation). The management system provides for the interaction between Moscow State Medical and Dental University named after A. I. Evdokimov with all interested organizations.

## VI. GENERAL QUESTIONS

In the general structure of providing medical care to patients in medical and preventive institutions of the dental profile, parodontitis is observed in any age group of patients and accounts for 30% of the total number of presentations.

Paodontal diseases (parodontopathies), along with caries, are the main mass lesions of the dental system. They are characterized by: latent onset, chronic course with frequent exacerbations, they are difficult to be diagnosed in the initial stages, and with the development of the process — to be treated. Therefore, parodontitis in untimely and / or improper treatment and progression of the process can cause tooth loss, development of purulent-inflammatory diseases of the maxillofacial region. The oral cavity of patients with this disease is a focus of intoxication and infectious sensitization of the body. As a result of the disease, the functional capabilities of the entire dental system are significantly reduced, which has a significant impact on the vital activity of the human body, its psycho-emotional state, and reduce the quality of life.

### DEFINITION OF THE CONCEPT

Parodontitis is a disease of the dental system characterized by the development of an acute or chronic inflammatory process, destruction of parodontal tissues and atrophy of the bone tissue of the alveoli. Kopeikin V. N. (1988) proposed a detailed definition of the concept – “parodontitis is the collective name of individual nosological forms of the maxillary system diseases, characterized by the development of a chronic or acute inflammatory process and the destruction of parodontal tissues, as well as atrophy of the bone tissue of the alveolar process (alveolar process) of the jaw”.

### ETIOLOGY AND PATHOGENESIS

This pathology is considered as one of the main causes of tooth loss in the adult population. In addition, parodontitis can be both a

consequence and a cause for the development of some general somatic diseases.

Parodontitis develops as a result of exposure to one or more etiological factors that can have both local (overload of the parodontium, damaging effect of microbial biofilm accumulation in the gingival crevice, iatrogenic causes) and general (vitamin deficiency, atherosclerotic vascular changes, endocrine pathology, decreased resistance of the body) character. It is important to understand that plaque and deposits do not always cause caries development, but they always cause the development of gingivitis. Gingivitis does not always result in parodontitis, but parodontitis is always preceded by gingivitis.

Under the influence of the damaging factor, pathological changes develop that cause a violation of the intratissue metabolism in parodontal tissues, which leads to partial death of the epithelium and destruction of the collagen fibers of the dental ligamentous apparatus, destruction of bone tissue, first in the cortical plate, and then the spongy substance.

Progression of bone resorption, loss of gum attachment to the bone and expansion of the periodontal pocket do not develop continuously, but in phases – active and inactive.

The pathological processes developing in the periodontal lead to an increase in the mobility of the tooth, as a result of which there is an increase in the influence of the mechanical factor on the vascular system, which contributes to the progression of inflammation and the increase in clinical manifestations.

In parodontitis caused by general somatic diseases, local factors aggravate the inflammatory process.

#### CLINICAL PRESENTATION.

Acute periodontitis, as an independent nosological form, is extremely rare, it develops due to an acute mechanical or chemical damage to the dentogingival junction. Acute parodontitis includes a parodontal abscess of gingival origin without a fistula and a parodontal abscess of gingival origin with a fistula. As a rule, they develop as a result of mechanical trauma. It is characterized by limited inflammation and bleeding of the gums; presence of a parodontal pocket and discharge of exudate from it; presence of a fistula (with a parodontal abscess of gingival origin with a fistula).

Chronic parodontitis always develops against the background of poor oral hygiene. As a rule, it is preceded by gingivitis. It is characterized by the presence of soft and hard dental deposits (supra – and subgingival); hyperemia, edema and bleeding of the gums; the presence of periodontal pockets and the release of exudate from them; pathological mobility of the teeth of various degrees; possible recession or hypertrophy of the gingival margin, deformation of the dentition, the appearance of teeth, diastemas and tooth interference (supracontacts).

The X-ray picture depends on the severity of parodontitis. The onset of the process is characterized by destruction of the cortical plate of the interalveolar septa vertices. Later, there is a truncation of the vertices, along with horizontal resorption there is also a vertical one, often with formation of bone pockets. The contours of the bone tissue of the alveolar processes have a characteristic scalloped appearance, a “pitted appearance”.

In patients with a localized form of parodontitis, these symptoms are detected only in a group of teeth, in a generalized form – in all teeth.

The severity of parodontitis is determined mainly by three leading symptoms — the depth of the periodontal pocket, the degree of bone resorption and, as a result, the pathological teeth mobility. These signs are taken as a basis for making the diagnosis and eveling i a treatment plan. Tooth mobility is an important metric criterion for assessing the condition of parodontal tissues. When planning treatment, examination of dental mobility is a mandatory diagnostic measure. The most common, when assessing the mobility of teeth, is Entin classification, as well as Miller classification which is also used in Flezar modification. See Appendix 3

On the basis of clinical and additional methods of examination, an odontoparodontogram is filled in according to V. Yu. Kurlandsky. See Appendix 16.

#### CLASSIFICATION OF PARODONTITIS BY ICD-10.

##### K05. 2 Acute periodontitis

K05. 20 Periodontal abscess [parodontal abscess] of gingival origin without a fistula. Periodontal abscess of gingival origin, not associated with a fistula. Excluded: acute apical periodontitis of pulpar origin (K04. 4); acute periapical abscess of pulpar origin (K04. 6; K04. 7).

K05. 20 Periodontal abscess [parodontal abscess] of gingival origin without a fistula. Excluded: acute apical periodontitis of pulpar origin (K04. 4); acute periapical abscess of pulpar origin (K04. 6; K04. 7).

K05. 22 Acute pericoronitis

K05. 28 Other specified acute periodontitis

K05. 29 Acute periodontitis, unspecified

K05. 3 Chronic periodontitis

K05. 30 Localized

K05. 31 Generalized

K05. 32 Chronic pericoronitis

K05. 33 Thickened follicle (papilla hypertrophy)

K05. 38 Other specified chronic periodontitis

K05. 39 Chronic periodontitis, unspecified

## GENERAL APPROACHES TO THE DIAGNOSIS OF PARODONTITIS

The diagnosis of parodontitis is made by taking the history, clinical examination and additional examination methods and is aimed at determining the periodontal status, severity and prevalence of the disease, as well as developing a comprehensive treatment plan.

In addition, the diagnosis should additionally be aimed at identifying factors that prevent the immediate start of treatment. Such factors can be:

- the presence of intolerance to medicines and materials used for treatment;

- concomitant diseases that complicate treatment;

- acute inflammatory diseases of oral organs and tissues;

- life-threatening acute condition/disease or exacerbation of a chronic disease (including myocardial infarction, acute cerebrovascular accident) that developed less than 6 months before seeking this dental care and other severe general somatic conditions;

- the patient's refusal from treatment.

## GENERAL APPROACHES TO THE DIAGNOSIS OF PARODONTITIS

Treatment of parodontal diseases should be comprehensive.

The principles of treating patients with parodontitis provide for simultaneous solving several tasks:

- ✓ resolution of inflammatory processes in the parodontium
- ✓ prevention of further development of the pathological process;
- ✓ preservation and restoration of the dental system function;
- ✓ prevention of the development of general and local complications;
- ✓ prevention of negative impact on the general health and quality of life of patients.

Treatment is a combination of etiotropic, pathogenetic and symptomatic therapy. Parodontitis is irreversible. The disease has no reverse development, but can only be stabilized thanks to the significant efforts of dentists of all profiles, the use of a complex of therapeutic measures and means.

Treatment of acute forms of parodontitis involves emergency measures aimed at inflammation resolution (incision and drainage of a periodontal abscess, incision and drainage of a submucosal or subperiosteal focus, etc.).

The choice of means and methods for the treatment of chronic parodontitis is determined by the severity and features of disease's clinical course. In the complex therapy for periodontitis, therapeutic (non-drug and medicinal), surgical, orthodontic and orthopedic treatment are used, aimed at eliminating inflammation in the parodontal tissues, eliminating the periodontal pocket, stimulating reparative osteogenesis, restoring the function of the dental system.

Therapeutic treatment of parodontitis is based on the use of non-surgical methods and is the basic or the initial stage of complex treatment for parodontal diseases and is aimed primarily at eliminating one of the etiological factors of the disease – bacterial biofilm and factors that ensure its accumulation on the tooth, and includes:

- ✓ conducting professional oral hygiene;
- ✓ training and monitoring the individual oral hygiene;
- ✓ removal of supra- and subgingival dental deposits;
- ✓ correction and elimination of factors that contribute to the maintenance of inflammatory processes in the parodontium, such as: overhanging fillings, carious cavities, wedge-shaped defects.
- ✓ elimination of premature contacts – functional selective grinding.
- ✓ prescribing and / or conducting antimicrobial and anti-inflammatory therapy.

Surgical treatment is aimed at eliminating the foci of inflammation that could not be eliminated at the stages of therapeutic treatment. It is unacceptable to perform planned surgical interventions without prior preparation within the framework of basic therapy and a thorough assessment of the results obtained.

Orthodontic treatment is aimed at eliminating dento-facial anomalies and secondary deformities of the dental arches, stabilizing pathological processes in the parodontium.

Orthopedic treatment is aimed at restoring the function of the dental system, restoring the integrity of the dentition, stabilizing pathological processes in the parodontium, creating conditions for the functioning of the dental system in a compensated state and includes the manufacture of removable and/or non-removable splinting orthopedic structures. Restoration of the dental system to a subcompensated state and stabilization of the pathological process at this level can be considered as a positive result of the treatment for moderate and severe stages of parodontitis .

Without orthopedic intervention (permanent splinting) it is impossible.

Dynamic monitoring is carried out every 1, 2, 6 weeks to monitor oral hygiene and determine the parodontal status, later – every 6 months.

Only those materials and medicines that are approved for use in accordance with the established procedure can be used to provide assistance.

## ORGANIZATION OF MEDICAL CARE FOR PATIENTS WITH PARODONTITIS

Treatment of patients with parodontitis is carried out in dental medical organizations. As a rule, treatment is carried out in outpatient conditions.

Assistance to patients with parodontitis is provided by general dentists, dental therapists, orthopedic dentists, dental surgeons, orthodontists, dentists. In the process of providing assistance, secondary medical personnel, including dental technicians and dental hygienists, take part.

VII. CHARACTERISTICS OF CLINICAL RECOMMENDATIONS REQUIREMENTS

**7.1. Patient's Model**

**Nosological form:** parodontal abscess of gingival origin without a fistula

**Stage:** any

**Phase:** Acute

**Complication:** no complications.

**ICD-C-3 code :** K05. 20

**7.1.1. Criteria and signs that determine the patient's model**

- ✓ patients with permanent teeth
- ✓ soft, hard dental deposits
- ✓ the gum is hyperemic, swollen
- ✓ soreness during palpation of the gums
- ✓ pathological mobility of a particular tooth/teeth
- ✓ limited infiltration
- ✓ presence of a parodontal pocket
- ✓ during palpation, purulent exudate is discharged from the periodontal pocket
- ✓ the pathological process may involve parodontal tissues of one and / or several teeth, both located adjacently and on different parts of the jaw
- ✓ increase in body temperature is possible;
- ✓ the X-ray shows signs of bone resorption in the alveolar walls

**7.1.2. The procedure for including the patient in Clinical recommendations (treatment protocols)**

The patient's condition that meets the criteria and signs of diagnosis of this patient model.

**7.1.3. Requirements for the outpatient diagnosis**

Code	Name	Frequency of execution
A01.07.001	Taking the history and complaints in oral pathology	1
A01.07.005	Visual examination of the maxillofacial region.	1

A01.07.02	Visual examination in oral pathology	1
A01.07.003	Palpation of the oral organs 1	1
A01.07.006	Palpation of the maxillofacial region.	1
A02.07.007	Teeth percussion	1
A02.07.008	Determination of the degree of tooth mobility.	1
A02.07.006	Occlusion detection	1
A02.07.003	Examination of parodontal pockets using a periodontal probe	According to the algorithm
A03.07.003	Diagnostics of the dento-facial system using methods and means of radiation imaging	1
A05.07.001	Electrodontometry	As needed
A12.07.002	Computer diagnostics of parodontal diseases using electronic probing devices	As needed
A12.07.001	Vital staining of hard dental tissues	As needed
A12.07.003	Determination of oral hygiene indices	As needed
A12.07.004	Determination of parodontal indices	As needed
A02.07.001	Oral examination with the help of additional tools	According to the algorithm
A06.07.003	Targeted intraoral contact radiography	1
A06.07.004	Orthopantomography	As needed
A06.07.007	Intraoral radiography in occlusion	As needed
A06.07.010	Palpation of the maxillofacial region.	As needed
A06.31.006	Description and interpretation of radiographic images	As needed
A09.07.002	Cytological examination of the cyst (abscess) contents of the oral cavity or the contents of a dental pocket	As needed
B01.065.001	Attendance (examination, consultation) of a dentist therapist, primary	1
B01.066.001	Attendance (examination, consultation) of a dentist orthopedist, primary	As needed
B01.067.001	Attendance (examination, consultation) of a dental surgeon, primary	As needed

\* “1” – if once; “according to the algorithm” – if it is necessary to do several times (2 or more); “as needed” – if it is not necessary (at the discretion of the attending physician)

#### **7.1.4. Characteristics of algorithms and features of performing diagnostic measures**

Diagnostics is aimed at making the diagnosis that corresponds to the patient's model, excluding complications, determining the opportunity to start treatment without additional diagnostic and therapeutic and preventive measures.

For this purpose, all patients by all means undergo taking their history, an examination of the mouth and teeth, as well as other necessary examinations, the results of which are entered in the medical card of the dental patient (form 043/y).

### **Taking the history**

When taking the history, complaints and the timing of their onset are found out. As a rule, the patient complains of swelling of the gums, pain when biting on the tooth, mobility of the tooth. In some cases, the patient notes the discharge of pus from the gum. There may be a deterioration in the general condition of the patient, fever, headaches, appetite and sleep disorders. The patient may note that earlier, after spontaneous opening of the abscess, pain and swelling of the gums decreased or passed completely.

The presence of general somatic diseases in the patient, his allergic history are identified. The dentist finds out whether the patient performs proper hygienic care of the mouth.

### **Visual examination, external examination of the maxillofacial area, examination with additional tools**

When examining the maxillofacial region, the presence of visible changes is noted, the lymph nodes of the head and neck are palpated bimanually and bilaterally, comparing the right and left halves.

When examining the mouth, the condition of the dentition, the mucous membrane of the mouth and throat, its color, moisture content, the presence of pathological changes are evaluated. Attention is paid to the depth of the vestibule, the nature of the lingual frenulum and the labial frenulum attachment, strands of the mucous membrane in the vestibule of the mouth. The dentist determines the state of occlusion, anomalies in the position of individual teeth, as well as the dentition as a whole, the presence of tremas, diastemas.

All teeth are subject to examination. Examination begins with the upper right molars and ends with the lower right molars.

All surfaces of each tooth are examined. The probe determines the density of hard tissues, attention is paid to the presence of spots and carious cavities. The dentist notes incorrectly made fillings, orthopedic and orthodontic structures, as well as the level of care for prostheses (satisfactory, unsatisfactory).

Palpation, percussion, determination of tooth mobility, examination of parodontal tissues, radiography are performed. See Appendices №3, №4, №10.

The teeth located in the area of the abscess are examined in detail: swelling is determined on the gum, if it is painful on palpation, if the mucous membrane is hyperemic and edematous.

When probing, a periodontal pocket with a purulent discharge can be determined.

When examining the teeth located next to the abscess, their mobility and sharply painful percussion may be noted.

When assessing the level of hygiene, the following is taken into account: when and how often the patient brushes his teeth; the method of cleaning; what pastes, brushes he uses and how often he changes them; whether he uses additional hygiene products. The clinical condition of the parodontium is determined on the basis of periodontal indices. Oral hygiene indices are determined before treatment and after oral hygiene training. See Appendices №2, №6.

Among the additional methods of examination, methods of X-ray diagnostics and microbiological examination are used.

### **7.1.5. Requirements for the outpatient treatment**

Code	Name	Frequency of execution
A16. 07. 051	Professional oral and dental hygiene	According to the algorithm
A13.30.007	Training in oral hygiene.	According to the algorithm
A14.07.004	Controlled brushing of teeth	According to the algorithm
B01.003.004.001	Local anesthesia	As needed
A16. 07. 011	Opening of the submucosal or subperiosteal focus of inflammation	As needed
A16.07.043	Closed curettage for parodontal	As needed

	diseases	
A 22.07.002	Ultrasound removal of supra-gingival and subgingival dental deposits	As needed
A 16.07.022	Removal of supra-gingival and subgingival dental deposits	According to the algorithm
A16.07.057	Removal of a fixed orthopedic structure	As needed
A16.07.001	Tooth extraction	As needed
A25.07.001	Prescription of drug therapy for diseases of the mouth and teeth	As needed
B01. 067. 02	Attendance (examination, consultation) of a dental surgeon, repeated	As needed
B01.066.02	Attendance (examination, consultation) of a dentist orthopedist, repeated	As needed
B01.065.002	Attendance (examination, consultation) of a dentist therapist, repeated	1

\* “1” – if once; “according to the algorithm” – if it is necessary to do several times (2 or more); “as needed” – if it is not necessary (at the discretion of the attending physician)

### **7.1.6. Characteristics of algorithms and features of performing drug-free assistance**

Non-drug dental care involves emergency measures aimed at relieving inflammation (opening of a periodontal abscess, removal of supra-gingival and sub-gingival dental deposits). If it is impossible

to stop the inflammatory process, tooth extraction is performed. See Appendices № 11, 12.

If necessary, the removal of an improperly manufactured fixed orthopedic structure (prosthesis) is carried out and a temporary structure is made. See Appendix № 7.

Ensuring proper oral hygiene helps to prevent the re-development of inflammatory periodontal diseases (the level of evidence strength C).

In order to develop the patient’s skills of oral care (brushing teeth) and the most effective removal of soft plaque from the teeth surfaces, the patient is taught oral hygiene techniques. Oral hygiene products are chosen individually. See Appendix № 5, 6.

After the relief of acute inflammatory phenomena (in case of tooth preservation), the patient is treated in accordance with the “Chronic localized periodontitis”model.

**7.1.7. Requirements for pharmaceutical outpatient medical care**

Name of the group	Frequency (duration of treatment)
Antimicrobials for local treatment of oral diseases	According to the algorithm
Preparations for local anesthesia	As needed
Antimicrobials for systemic use	As needed
Nonsteroidal anti-inflammatory drugs;	As needed
Antihistamines	As needed

**7.1.8. Characteristics of algorithms and features of the use of pharmaceutical means**

Before performing manipulations, if medically required, anesthesia is performed (application, infiltration, conductor), before anesthesia, the injection site is treated with an application anesthetic, if necessary.

The basis of medical treatment of parodontitis is antiseptics. They are used in the form of oral baths, applications and irrigation.

Non-steroidal anti-inflammatory drugs are prescribed to relieve pain and edema. Antihistamines are prescribed if necessary after surgical interventions. Local use of antibacterial drugs is acceptable.

**7.1.9. Requirements for the regime of work, rest, treatment and rehabilitation**

The patient is recommended to come for an examination the next day after the therapeutic measures. The subsequent schedule of visits is prescribed individually, depending on the course of the inflammatory process.

On the first day, it is recommended not to overheat the body and exclude physical activity.

**7.1.10. Requirements for patient care and auxiliary procedures**

There are no special requirements.

### **7.1.11. Requirements for dietary prescriptions and restrictions**

After opening a periodontal abscess or extracting a tooth, it is not recommended to eat for two hours. On the first day, rough, hot food intake should be avoided.

### **7.1.12. The form of the patient's informed voluntary consent when implementing Clinical recommendations (treatment protocols)**

See Appendix № 8.

### **7.1.13. Additional information for the patient and his family members**

See Appendix № 9.

### **7.1.14. Rules for changing the requirements when implementing Clinical recommendations (treatment protocols) "Parodontitis" and termination of the requirements of Clinical recommendations (treatment protocols)**

If signs requiring preparatory measures for treatment are detected during the process of making the diagnosis, the patient is transferred to Clinical recommendations (treatment protocols) corresponding to the identified diseases and complications.

If signs of another disease requiring diagnostic and therapeutic measures are detected, along with signs of parodontitis, medical care is provided to the patient in accordance with the requirements of:

a) a section of these Clinical recommendations (treatment protocols) corresponding to a parodontal abscess of gingival origin without a fistula;

b) Clinical recommendations (treatment protocols) with the identified disease or syndrome.

### **7.1.15. Possible outcomes and their characteristics**

Name of the outcome	Frequency of development, %	Criteria and Signs	Estimated time to reach the outcome	Continuity and phasing of medical care
Function compensation	80	No signs of gum inflammation	In 7 days	Providing medical care according to

				the model of localized chronic periodontitis
Stabilization	10	Absence of disease progression	In 7 days	Providing medical care according to the model of localized chronic periodontitis
Development of iatrogenic complications	5	The onset of new lesions or leveling in caused by the therapy (for example, allergic reactions)	At any stage	Provision of medical care according to the protocol of appropriate care
Development of a new disease associated with the underlying medical condition	5	Recurrent periodontal abscess	At any stage in the absence of treatment	Provision of medical care according to the protocol of appropriate care

### 7.1.16. Cost characteristics of Clinical recommendations (treatment protocols)

“Parodontitis”. The cost characteristics are determined according to the requirements of regulatory documents.

### 7.2 Patient’s Model

**Nosological form:** parodontal abscess of gingival origin with a fistula

**Stage:** any

**Phase:** Acute

**Complication:** no complications.

**ICD-C-3 code : K05. 20**

**7.2.1. Criteria and signs that determine the patient’s model**

- ✓ patients with permanent teeth
- ✓ a fistulous tract with a purulent discharge is determined
- ✓ soft, hard dental deposits
- ✓ the gum is hyperemic, swollen
- ✓ soreness during palpation of the gums
- ✓ pathological mobility of a particular tooth/teeth
- ✓ limited infiltration
- ✓ presence of a parodontal pocket
- ✓ the pathological process may involve parodontal tissues of one and / or several teeth, both located adjacently and on different parts of the jaw
- ✓ increase in body temperature is possible;
- ✓ the X-ray shows signs of bone resorption in the alveolar walls

**7.2.2. The procedure for including the patient in Clinical recommendations (treatment protocols)**

The patient’s condition that meets the criteria and signs of diagnosis of this patient model.

**7.2.3. Requirements for the outpatient diagnosis**

Code	Name	Frequency of execution
A01. 07.001	Taking the history and complaints in oral pathology	1
A01. 07.005	Visual examination of the maxillofacial region.	1
01.07.002	Visual examination in oral pathology	1
A01. 07.003	Palpation of the oral organs	1
A02. 07.007	Teeth percussion	1
A02. 07.008	Determination of the degree of tooth mobility.	1
A02.07.006	Occlusion detection	1
A02.07.003	Examination of parodontal pockets using a periodontal probe	According to the algorithm

A12.07.002	Computer diagnostics of parodontal diseases using electronic probing devices	As needed
A12.07.001	Vital staining of hard dental tissues	As needed
A12.07.003	Determination of oral hygiene indices	As needed
A12.07.004	Determination of parodontal indices	As needed
A02.07.001	Oral examination with the help of additional tools	According to the algorithm
A06.07.003	Targeted intraoral contact radiography	1
A06.07.004	Orthopantomography	As needed
A06.07.007	Intraoral radiography in occlusion	As needed
A06.07.010	Palpation of the maxillofacial region.	As needed
A06.31.006	Description and interpretation of radiographic images	As needed
B01.065.001	Attendance (examination, consultation) of a dentist therapist, primary	1
B01.066.01	Attendance (examination, consultation) of a dentist orthopedist, primary	As needed
B01.067.01	Attendance (examination, consultation) of a dental surgeon, primary	1

\* “1” – if once; “according to the algorithm” – if it is necessary to do several times (2 or more); “as needed” – if it is not necessary (at the discretion of the attending physician)

#### **7.2.4. Characteristics of algorithms and features of performing diagnostic measures**

Diagnostics is aimed at making the diagnosis that corresponds to the patient’s model, excluding complications, determining the opportunity to start treatment without additional diagnostic and therapeutic and preventive measures.

For this purpose, all patients by all means undergo taking their history, an examination of the mouth and teeth, as well as other necessary examinations, the results of which are entered in the medical card of the dental patient (form 043/y).

##### **Taking the history**

When taking the history, complaints and the timing of their onset are found out. As a rule, the patient complains of swelling and pain in the gums, pain when biting on the tooth, mobility of the tooth.

There may be a deterioration in the general condition of the patient, fever, headaches, appetite and sleep disorders. The patient may note that a similar condition was observed earlier and after the appearance of a

fistulous tract on the gum, the pain and swelling of the gum decreased or disappeared.

The presence of general somatic diseases in the patient, his allergic history are identified. The dentist finds out whether the patient performs proper hygienic care of the mouth.

Visual examination, external examination of the maxillofacial area, examination with additional tools

When examining the maxillofacial region, the presence of visible changes is noted, the lymph nodes of the head and neck are palpated bimanually and bilaterally, comparing the right and left halves.

When examining the mouth, the condition of the dentition, the mucous membrane of the mouth and throat, its color, moisture content, the presence of pathological changes are evaluated. Attention is paid to the depth of the vestibule, the nature of the lingual frenulum and the labial frenulum attachment, strands of the mucous membrane in the vestibule of the mouth. The dentist determines the state of occlusion, anomalies in the position of individual teeth, as well as the dentition as a whole, the presence of tremas, diastemas.

All teeth are subject to examination. Examination begins with the upper right molars and ends with the lower right molars.

All surfaces of each tooth are examined. The probe determines the density of hard tissues, attention is paid to the presence of spots and carious cavities. The dentist notes incorrectly made fillings, orthopedic and orthodontic structures, as well as the level of care for prostheses (satisfactory, unsatisfactory).

Palpation, percussion, determination of tooth mobility, examination of parodontal tissues, radiography are performed. In the area of the fistula: the gum is hyperemic, edematous, there is a fistulous tract with a purulent discharge, an infiltrate is determined by palpation; the teeth are mobile and painful with percussion. See Appendices №3, №4, №10.

Oral hygiene indices are determined before treatment and after oral hygiene training. When assessing the level of hygiene, the following is taken into account: when and how often the patient brushes his teeth; the method of cleaning; what pastes, brushes he uses and how often he changes them; whether he uses additional hygiene products. The quality control of tooth brushing is carried out using hygiene indices. The clinical

condition of the parodontium is determined on the basis of periodontal indices. See Appendices №2, №6.

Among the additional methods of examination, methods of X-ray diagnostics and microbiological examination are used.

### 7.2.5. Requirements for the outpatient treatment

Code	Name	Frequency of execution
A16. 07. 051	Professional oral and dental hygiene	According to the algorithm
A13.30.007	Training in oral hygiene.	According to the algorithm
A14.07.004	Controlled brushing of teeth	According to the algorithm
B01.003.004.001	Local anesthesia	As needed
A16.07.001	Tooth extraction	As needed
A16. 07. 011	Opening of the submucosal or sub-periosteal focus of inflammation	As needed
A16. 07. 043	Closed curettage for parodontal diseases	As needed
A 22.07.002	Ultrasound removal of supra-gingival and subgingival dental deposits	As needed
A 16.07.022	Removal of supra-gingival and subgingival dental deposits	According to the algorithm
A16.07.057	Removal of a fixed orthopedic structure	As needed
B01.065.02	Attendance (examination, consultation) of a dentist therapist, repeated	As needed
B01.066.02	Attendance (examination, consultation) of a dentist orthopedist, repeated	As needed
B01. 067. 02	Attendance (examination, consultation) of a dental surgeon, repeated	1
A25.07.001	Prescription of drug therapy for diseases of the mouth and teeth	As needed

\* "1" – if once; "according to the algorithm" – if it is necessary to do several times (2 or more); "as needed" – if it is not necessary (at the discretion of the attending physician)

### **7.2.6. Characteristics of algorithms and features of performing drug-free assistance**

Non-drug dental care involves emergency measures aimed at relieving inflammation (opening of a periodontal abscess, removal of supra-gingival and sub-gingival dental deposits). If it is impossible to stop the inflammatory process, tooth extraction is performed. See Appendices № 11, 12.

If necessary, the removal of an improperly manufactured fixed orthopedic structure (prosthesis) is carried out and a temporary structure is made.

Ensuring proper oral hygiene helps to prevent the re-development of inflammatory periodontal diseases (the level of evidence strength C).

In order to develop the patient's skills of oral care (brushing teeth) and the most effective removal of soft plaque from the teeth surfaces, the patient is taught oral hygiene techniques on a scheduled basis. Oral hygiene products are chosen individually. See Appendices №2, №6.

After the relief of acute inflammatory phenomena, the patient is treated in accordance with the "Chronic localized periodontitis" model.

### **7.2.7. Requirements for pharmaceutical outpatient medical care**

Name of the group	Frequency (duration of treatment)
Antimicrobials for local treatment of oral diseases	According to the algorithm
Preparations for local anesthesia	As needed
Antimicrobials for systemic use	As needed
Nonsteroidal anti-inflammatory drugs;	As needed
Antihistamines	As needed

### **7.2.8. Characteristics of algorithms and features of the use of pharmaceutical means**

Before performing manipulations, if medically required, anesthesia is performed (application, infiltration, conductor), before anesthesia, the injection site is treated with an application anesthetic, if necessary.

The basis of medical treatment of parodontitis is antiseptics. They are used in the form of oral baths, applications and irrigation. Non-steroidal anti-inflammatory drugs are prescribed to relieve pain and

edema. Antihistamines are prescribed if necessary after surgical interventions. Local use of antibacterial drugs is acceptable.

#### **7.2.9. Requirements for the regime of work, rest, treatment and rehabilitation**

The patient is recommended to come for an examination the next day after the therapeutic measures. The subsequent schedule of visits is prescribed individually, depending on the course of the inflammatory process.

On the first day, it is recommended not to overheat the body and exclude physical activity.

#### **7.2.10. Requirements for patient care and auxiliary procedures**

There are no special requirements.

#### **7.2.11. Requirements for dietary prescriptions and restrictions**

After performing surgical manipulations, it is not recommended to take food for two hours. On the day of surgical intervention, rough, hot food intake should be avoided.

#### **7.2.12. The form of the patient's informed voluntary consent when implementing Clinical recommendations (treatment protocols)**

See Appendix № 8.

#### **7.2.13. Additional information for the patient and his family members**

See Appendix № 9.

#### **7.2.14. Rules for changing the requirements when implementing Clinical recommendations (treatment protocols) "Parodontitis" and termination of the requirements of Clinical recommendations (treatment protocols)**

If signs requiring preparatory measures for treatment are detected during the process of making the diagnosis, the patient is transferred to Clinical recommendations (treatment protocols) corresponding to the identified diseases and complications.

If signs of another disease requiring diagnostic and therapeutic measures are detected, along with signs of parodontal abscess of gingival origin with a fistula, medical care is provided to the patient

in accordance with the requirements of:

a) a section of these Clinical recommendations (treatment protocols) corresponding to a parodontal abscess of gingival origin with a fistula;

b) Clinical recommendations (treatment protocols) with the identified disease or syndrome.

**7.2.15. Possible outcomes and their characteristics**

Name of the outcome	Frequency of development, %	Criteria and Signs	Estimated time to reach the outcome	Continuity and phasing of medical care
Function compensation	80	No signs of inflammation	In 7 days	Providing medical care according to the model of localized chronic periodontitis
Stabilization	10	Absence of disease progression	In 7 days	Providing medical care according to the model of localized chronic periodontitis
Development of iatrogenic complications	5	The onset of new lesions or eveling I on caused by the therapy (for example, allergic reactions)	At any stage	Provision of medical care according to the protocol of appropriate care
Development of a new disease associated	5	Recurrent periodontal abscess	At any stage in the absence	Provision of medical care according to the protocol

with the underlying medical condition			of treatment	of appropriate care
---------------------------------------	--	--	--------------	---------------------

**7.2.16. Cost characteristics of Clinical recommendations (treatment protocols) “Parodontitis”**

The cost characteristics are determined according to the requirements of regulatory documents.

**7.3. Patient’s Model**

**Nosological form:** localized chronic parodontitis

**Stage:** mild

**Phase:** stable course

**Complication:** no complications.

**ICD-10 code:** K05. 30

**7.3.1 Criteria and signs that determine the patient’s model**

- ✓ patients with permanent teeth
- ✓ there is a limited area of the lesion as a result of the influence of a specific etiological factor
- ✓ pathological mobility of a particular tooth of the 1<sup>st</sup> degree
- ✓ the depth of periodontal pockets is up to 4 mm
- ✓ unsatisfactory hygiene
- ✓ soft, hard dental deposits
- ✓ the gum is hyperemic, swollen
- ✓ swelling of the gums
- ✓ bleeding gums
- ✓ X-ray shows expansion of the periodontal fissure, resorption of the tips of the interdental septa to 1\3 of the root length, destruction of the cortical plate.

**7.3.2. The procedure for including the patient in Clinical recommendations (treatment protocols)**

The patient’s condition that meets the criteria and signs of diagnosis of this patient model.

### 7.3.3. Requirements for the outpatient diagnosis

Code	Name	Frequency of execution
A01.07.001	Taking the history and complaints in oral pathology	1
A01.07.005	Visual examination of the maxillofacial region.	1
A01.07.003	Palpation of the oral organs	1
A02.07.007	Teeth percussion	1
A02.07.005	Thermodiagnosis of the tooth	As needed
A02.07.008	Determination of the degree of tooth mobility.	According to the algorithm
A02.07.006	Occlusion detection	According to the algorithm
A02.07.003	Examination of parodontal pockets using a periodontal probe	According to the algorithm
A12.07.002	Computer diagnostics of parodontal diseases using electronic probing devices	As needed
A12.07.001	Vital staining of hard dental tissues	According to the algorithm
A12.07.003	Determination of oral hygiene indices	According to the algorithm
A12.07.004	Determination of parodontal indices	According to the algorithm
A02.07.001	Oral examination with the help of additional tools	1
A05.07.001	Electrodontometry	As needed
A03.07.003	Diagnostics of the dento-facial system using methods and means of radiation imaging	As needed
A06.07.003	Targeted intraoral contact radiography	As needed
A06.07.004	Orthopantomography	1
A06.07.007	Intraoral radiography in occlusion	As needed
A06.31.006	Description and interpretation of radiographic images	As needed
A06.07.010	Palpation of the maxillofacial region.	As needed
B01.065.01	Attendance (examination, consultation) of a dentist therapist, primary	1
B01.066.01	Attendance (examination, consultation) of a dentist orthopedist, primary	As needed

B01.067.01	Attendance (examination, consultation) of a dental surgeon, primary	As needed
B01.063.001	Attendance (examination, consultation) of a dental orthodontist, primary	As needed
B01.054.001	Examination (consultation) of a physiotherapist	As needed

### **7.3.4. Characteristics of algorithms and features of performing diagnostic measures**

Diagnostics is aimed at making the diagnosis that corresponds to the patient's model, excluding complications, determining the opportunity to start treatment without additional diagnostic and therapeutic and preventive measures.

For this purpose, all patients by all means undergo taking their history, an examination of the mouth and teeth, as well as other necessary examinations, the results of which are entered in the medical card of the dental patient (form 043/y).

#### **Taking the history**

When taking the history, complaints and the timing of their onset are found out. As a rule, the patient complains of pain from all types of irritants and / or spontaneous one; bleeding of the gums when brushing teeth, during meals or spontaneous; localized mobility of the teeth and their displacement, bad breath, defects in fillings and orthopedic structures, aesthetic discomfort. It is specified how many years the patient has been suffering from this disease or when the first symptoms appeared, whether he was treated earlier for this disease, the nature of the treatment, its volume (according to the patient) is found out, the result (sustained improvement, temporary improvement, without improvement or deterioration).

The presence of general somatic diseases in the patient, his allergic history are identified. The dentist finds out whether the patient performs proper hygienic care of the mouth.

Visual examination, external examination of the maxillofacial area, examination with additional tools.

When examining the maxillofacial region, the presence of visible changes is noted, the lymph nodes of the head and neck are palpated bimanually and bilaterally, comparing the right and left halves.

When examining the mouth, the condition of the dentition, the mucous membrane of the mouth and throat, its color, moisture content, the presence of pathological changes are evaluated. Special attention is paid to the depth of the vestibule, the nature of the lingual frenulum and the labial frenulum attachment, strands of the mucous membrane in the vestibule of the mouth. The dentist determines the state of occlusion, anomalies in the position of individual teeth, as well as the dentition as a whole, the presence of tremas, diastemas.

The dentist also determines the condition of the mucous membrane, its color, the degree of edema, the degree of moisture, the nature of saliva.

Assessment of periodontal tissues condition is carried out by probing using a periodontal probe (as well as electronic probing devices). At this, the presence of bleeding gums, the depth of the periodontal pocket, the magnitude of the gum recession, the presence of dental deposits and their nature, the presence of a discharge from the periodontal pocket are evaluated. Probing of the periodontal pocket is carried out in 6 points of each tooth (vestibulo-distal, vestibular, vestibulo-medial, lingual-distal, lingual and lingual-medial). In multi-root teeth, the presence of furcation defects and their class are evaluated using a furcation probe. See Appendices №4, №10.

Tooth mobility is an important metric criterion for assessing the condition of parodontal tissues. When planning treatment, examination of dental mobility is a mandatory diagnostic measure. When assessing teeth mobility, the most common is Entin classification, as well as Miller classification and Flezar modification. See Appendix №3

Occlusal contacts are evaluated using articulation paper, wax plates and / or electronic devices.

Special attention is paid to identification of improperly manufactured fillings, the functional state of existing orthopedic structures (removable and non-removable), orthodontic devices, as well as the correct care of prostheses.

On the basis of clinical and additional methods of examination, an odontoparodontogram is filled in according to V. Yu. Kurlandsky. See Appendix №16.

When assessing the level of hygiene, attention is paid to the patient's hygiene skills in mouth care: when, how many times a day he brushes his

teeth, the method of cleaning, which pastes and brushes he uses, how often he changes them. Dental plaque indicators and hygiene indices are used to control the quality of tooth brushing. In addition to hygiene indices, the bleeding index is calculated to determine the degree of gum inflammation. See Appendices №2, №6.

As additional methods of examination, methods of X-ray diagnostics, microbiological and cytological studies, etc. are used.

### 7.3.5. Requirements for the outpatient treatment

Execution code	Name	Frequency
A01. 07. 001	Taking the history and complaints in oral pathology	1
A01. 07. 005	Visual examination of the maxillofacial region.	1
A01. 07. 003	Palpation of the oral organs	1
A02. 07. 007	Teeth percussion	1
A02. 07. 005	Thermodiagnosis of the tooth	As needed
A02. 07. 008	Determination of the degree of tooth mobility.	According to the algorithm
A02. 07. 006	Occlusion detection	According to the algorithm
A02. 07. 003	Examination of parodontal pockets using a periodontal probe	According to the algorithm
A12. 07. 002	Computer diagnostics of parodontal diseases using electronic probing devices	As needed
A12. 07. 001	Vital staining of hard dental tissues	According to the algorithm
A12. 07. 003	Determination of oral hygiene indices	According to the algorithm
A12. 07. 004	Determination of parodontal indices	According to the algorithm
A02. 07. 001	Oral examination with the help of additional tools	1
A05. 07. 001	Electrodontometry	As needed
A03. 07. 003	Diagnostics of the dento-facial system using methods and means of radiation imaging	As needed
A06.07.003	Targeted intraoral contact radiography	As needed

A06.07.004	Orthopantomography	1
A06.07.007	Intraoral radiography in occlusion	As needed
A06.31.006	Description and interpretation of radiographic images	As needed
A06.07.010	Palpation of the maxillofacial region.	As needed
B01.065.01	Attendance (examination, consultation) of a dentist therapist, primary	1
B01.066.01	Attendance (examination, consultation) of a dentist orthopedist, primary	As needed
B01.067.01	Attendance (examination, consultation) of a dental surgeon, primary	As needed
B01.063.001	Attendance (examination, consultation) of a dental orthodontist, primary	As needed
B01.054.001	Examination (consultation) of a physiotherapist	As needed

\* “1” – if once; “according to the algorithm” – if it is necessary to do several times (2 or more); “as needed” – if it is not necessary (at the discretion of the attending physician)

### **7.3.6. Characteristics of algorithms and features of performing drug-free assistance**

Drug-free assistance is aimed at eliminating one of the main etiological factors of parodontal diseases – bacterial biofilm and factors that ensure its accumulation. When removing dental deposits, it is a prerequisite to create a clean, biocompatible, smooth root surface by removing destroyed and infected tissues. At this, antiseptics and local antibiotics are considered as additional means. See Appendix №12.

Drug-free assistance also includes surgical, orthopedic and orthodontic treatment. See Appendices №7, №11, №14, №15.

### **7.3.7. Requirements for pharmaceutical outpatient medical care**

Name of the group	Frequency (duration of treatment)
Antimicrobials for local treatment of oral diseases	According to the algorithm
Preparations for local anesthesia	As needed
Antimicrobials for systemic use	As needed
Nonsteroidal anti-inflammatory drugs;	As needed
Antihistamines	As needed

### **7.3.8. Characteristics of algorithms and features of the use of pharmaceutical means**

Before performing manipulations, if medically required, anesthesia is performed (application, infiltration, conductor), before anesthesia, the injection site is treated with an application anesthetic, if necessary. Additionally, therapeutic toothpastes based on antiseptics and other anti-inflammatory agents are used.

The basis of medical treatment of parodontitis is antiseptics. They are used in the form of oral baths, applications and irrigation. Non-steroidal anti-inflammatory drugs are prescribed to relieve pain and edema.

Antihistamines are prescribed after surgical interventions.

Antimicrobials of systemic action are prescribed for intoxication and complications after surgery.

### **7.3.9. Requirements for the regime of work, rest, treatment and rehabilitation**

After the treatment, dynamic monitoring is necessary – 2 times during the first year. Later, once a year with a control radiography.

### **7.3.10. Requirements for patient care and auxiliary procedures**

There are no special requirements.

### **7.3.11. Requirements for dietary prescriptions and restrictions**

After performing surgical manipulations, it is not recommended to take food for two hours. On the day of surgery, it is recommended to avoid eating rough, hot food and not to chew on the operated side, not to warm it.

### **7.3.12. The form of the patient's informed voluntary consent when performing clinical recommendations (treatment protocols)**

See Appendix № 8.

### **7.3.13. Additional information for the patient and his family members**

See Appendix № 9.

**7.3.14. Rules for changing the requirements when implementing Clinical recommendations (treatment protocols) “Parodontitis” and termination of the requirements of Clinical recommendations (treatment protocols)**

If signs requiring preparatory measures for treatment are detected during the process of making the diagnosis, the patient is transferred to Clinical recommendations (treatment protocols) corresponding to the identified diseases and complications.

If signs of another disease requiring diagnostic and therapeutic measures are detected, along with signs of parodontitis, medical care is provided to the patient in accordance with the requirements of:

- a) the section of these Clinical recommendations (treatment protocols) corresponding to parodontitis;
- b) Clinical recommendations (treatment protocols) with the identified disease or syndrome.

**7.3.15. Possible outcomes and their characteristics**

Name of the outcome	Frequency of development, %	Criteria and Signs	Estimated time to reach the outcome	Continuity and phasing of medical care
Function compensation	75	No inflammation. Reduction or absence of pathological tooth mobility	After treatment, 7 days	Dynamic observation 2 times during the first year. Later, once a year.
Stabilization	15	Lack of both positive and negative dynamics	After treatment, 7 days	Dynamic observation 2 times during the first year. Later, once a year.
Development of iatrogenic complications	5	The onset of new lesions or leveling	At any stage	Provision of medical care

		108ion caused by the therapy (for example, allergic reactions)		according to the protocol of ppropriate care
Development of a new disease associated with the underlying medical condition	5	Relapse of periodontitis, its progression	In the absence of supportive parodontal treatment	Provision of medical care according to the protocol of ppropriate care

### 7.3.16. Cost characteristics of Clinical recommendations (treatment protocols) “Parodontitis”

The cost characteristics are determined according to the requirements of regulatory documents.

#### 7.4. Patient’s Model

**Nosological form:** localized chronic periodontitis

**Stage:** Moderate

**Phase:** stable course

**Complication:** no complications.

**ICD-10 code:** K05. 30

#### 7.4.1. Criteria and signs that determine the patient’s model

- ✓ patients with permanent teeth
- ✓ there is a limited area of the lesion as a result of the influence of a specific etiological factor
- ✓ pathological mobility of teeth of the 2<sup>nd</sup> degree
- ✓ the depth of periodontal pockets is up to 6 mm
- ✓ unsatisfactory hygiene
- ✓ soft, hard dental deposits
- ✓ the gum is hyperemic, swollen
- ✓ swelling of the gums
- ✓ bleeding gums

- ✓ exposure of the teeth roots
- ✓ radiology determines:
- ✓ expansion of the periodontal fissure, resorption of the tips of the interdental septa to 1\2 of the root length, destruction of the cortical plate.

#### **7.4.2. The procedure for including the patient in Clinical recommendations (treatment protocols)**

The patient's condition that meets the criteria and signs of diagnosis of this patient model.

#### **7.4.3. Requirements for the outpatient diagnosis**

Code	Name	Frequency of execution
A01. 07.001	Taking the history and complaints in oral pathology	1
A01. 07.005	Visual examination of the maxillofacial region.	1
A01. 07.003	Palpation of the oral organs	1
A02. 07.007	Teeth percussion	1
A02. 07.005	Thermodiagnosis of the tooth	As needed
A02. 07.008	Determination of the degree of tooth mobility.	According to the algorithm
A02. 07.006	Occlusion detection	According to the algorithm
A02. 07.003	Examination of parodontal pockets using a periodontal probe	According to the algorithm
A12. 07.002	Computer diagnostics of parodontal diseases using electronic probing devices	As needed
A12. 07.001	Vital staining of hard dental tissues	According to the algorithm
A12. 07.003	Determination of oral hygiene indices	According to the algorithm
A12. 07.004	Determination of parodontal indices	As needed
A02. 07.001	Oral examination with the help of additional tools	1
A05. 07.001	Electrodontometry	As needed
A03. 07.003	Diagnostics of the dento-facial system using methods and means of radiation	As needed

	imaging	
A06.07.003	Targeted intraoral contact radiography	As needed
A06.07.004	Orthopantomography	1
A06.07.007	Intraoral radiography in occlusion	As needed
A06.31.006	Description and interpretation of radiographic images	As needed
A06.07.010	Palpation of the maxillofacial region.	As needed
B01.066.01	Attendance (examination, consultation) of a dentist orthopedist, primary	1
B01.065.01	Attendance (examination, consultation) of a dentist therapist, primary	1
B01.067.01	Attendance (examination, consultation) of a dental surgeon, primary	As needed
B01.063.001	Attendance (examination, consultation) of a dental orthodontist, primary	As needed
B01.054.001	Examination (consultation) of a physiotherapist	As needed

\* “1” – if once; “according to the algorithm” – if it is necessary for several times (2 or more); “as needed” – if not necessary (at the discretion of the attending physician)

#### **7.4.4. Characteristics of algorithms and features of performing diagnostic measures**

Diagnostics is aimed at making the diagnosis that corresponds to the patient’s model, excluding complications, determining the opportunity to start treatment without additional diagnostic and therapeutic and preventive measures.

For this purpose, all patients by all means undergo taking their history, an examination of the mouth and teeth, as well as other necessary examinations, the results of which are entered in the medical card of the dental patient (form 043/y).

#### **Taking the history**

When taking the history, complaints and the timing of their onset are found out. As a rule, the patient complains of pain from all types of irritants and / or spontaneous; bleeding of the gums when brushing teeth, during meals or spontaneous; localized mobility of the teeth and their displacement, bad breath, defects in fillings and orthopedic structures, aesthetic discomfort. It is specified how many years the patient has been suffering from this disease or when the first symptoms appeared, whether

he was treated earlier for this disease, the nature of the treatment, its volume (according to the patient) is found out, the result (sustained improvement, temporary improvement, without improvement or deterioration).

The presence of general somatic diseases in the patient, his allergic history are identified. The dentist finds out whether the patient performs proper hygienic care of the mouth.

Visual examination, external examination of the maxillofacial area, examination with additional tools

When examining the maxillofacial region, the presence of visible changes is noted, the lymph nodes of the head and neck are palpated bimanually and bilaterally, comparing the right and left halves.

When examining the mouth, the condition of the dentition, the mucous membrane of the mouth and throat, its color, moisture content, the presence of pathological changes are evaluated. Special attention is paid to the depth of the vestibule, the nature of the lingual frenulum and the labial frenulum attachment, strands of the mucous membrane in the vestibule of the mouth. The dentist determines the state of occlusion, anomalies in the position of individual teeth, as well as the dentition as a whole, the presence of tremas, diastemas.

The dentist also determines the condition of the mucous membrane, its color, the degree of edema, the degree of moisture, the nature of saliva.

Assessment of periodontal tissues condition is carried out by probing using a periodontal probe (as well as electronic probing devices). At this, the presence of bleeding gums, the depth of the periodontal pocket, the magnitude of the gum recession, the presence of dental deposits and their nature, the presence of a discharge from the periodontal pocket are evaluated. Probing of the periodontal pocket is carried out at 6 points of each tooth (vestibulo-distal, vestibular, vestibulo--medial, lingual-distal, lingual and lingual-medial). In multi-root teeth, the presence of furcation defects and their class are evaluated using a furcation probe. See Appendices №4, №10.

Tooth mobility is an important metric criterion for assessing the condition of parodontal tissues. When planning treatment, examination of dental mobility is a mandatory diagnostic measure. When assessing teeth

mobility, the most common is Entin classification, as well as Miller classification and Flezar modification. See Appendix №3

Occlusal contacts are evaluated using articulation paper, wax plates and / or electronic devices.

Special attention is paid to the identification of improperly manufactured fillings, the functional state of existing orthopedic structures (removable and non-removable), orthodontic devices, as well as the correct care of prostheses.

On the basis of clinical and additional methods of examination, an odontoparodontogram is filled in according to V. Yu. Kurlandsky. See Appendix №16.

When assessing the level of hygiene, attention is paid to the patient's hygiene skills in

mouth care: when, how many times a day he brushes his teeth, the method of cleaning, which pastes and brushes

it uses, how often he changes them. Dental plaque indicators and hygiene indices are used to control the quality of tooth brushing. In addition to hygiene indices, the bleeding index is calculated to determine the degree of gum inflammation. See Appendices №2, №6.

As additional methods of examination, methods of X-ray diagnostics, microbiological and cytological studies, etc. are used.

At the end of the examination, which is carried out jointly with dental surgeons, orthopedic dentists, orthodontists, a comprehensive treatment plan is drawn up.

#### **7.4.5. Requirements for the outpatient treatment**

Code	Name	Frequency of execution
A14. 07. 003	Oral hygiene	According to the algorithm
A16.07.055	Professional oral and dental hygiene	According to the algorithm
A13.31.007	Training in oral hygiene.	According to the algorithm
A14. 07. 004	Controlled brushing of teeth	According to the algorithm
B01.003.004.001	Local anesthesia	As needed
A 22.07.002	Ultrasound removal of supra-gingival	As needed

	and subgingival dental deposits	
A 16.07.022	Removal of supra-gingival and subgingival dental deposits	According to the algorithm
A22. 07. 001	Ultrasound treatment of periodontal pockets	As needed
A16. 07. 043	Closed curettage for parodontal diseases	According to the algorithm
A 16.07.001	Tooth extraction	As needed
A16.07.021	Temporary splinting in parodontal diseases	As needed
A16.07.029	Algorithm of selective grinding of hard dental tissues	According to the algorithm
A16.07.030	Gingivectomy.	As needed
A16.07.048	Frenuloplasty	As needed
A16.07.046	Plastic surgery of the upper lip frenulum	As needed
A16.07.047	Plastic surgery of the lower lip frenulum	As needed
A16.07.049	Vestibuloplasty	As needed
A16.07.044	Flap surgery	As needed
A16.07.064	Coronary-radicular separation	As needed
A16.07.063	Hemisection	As needed
A16.07.002	Tooth restoration with a filling	As needed
A16.07.003	Restoration of the tooth with inlays, veneers, a three-quarter crown	As needed
A16.07.004	Tooth restoration with a crown	As needed
A16.07.005	Restoration of the dentition integrity with fixed bridge prosthesis	As needed
A16.07. 039	Prosthetics with partial removable laminar dentures	As needed
A16.07.00	Prosthetics with removable clasp prostheses	As needed

A16.07.057	Removal of a fixed orthopedic structure	As needed
A16.07.038	Restoration of the dentition integrity with removable bridge prosthesis	As needed
A17.07.002	Physiotherapy effect on the maxillofacial area	As needed
A16.07.053	Re-fixation of fixed orthopedic structures on permanent cement	As needed
A16.07.041	Permanent splinting with solid-cast removable structures for parodontal diseases	As needed
A25.07.001	Prescription of drug therapy for diseases of the mouth and teeth	As needed
B01.065.02	Attendance (examination, consultation) of a dentist therapist, repeated	1
B01.066.02	Attendance (examination, consultation) of a dentist orthopedist, repeated	1
B01.067.02	Attendance (examination, consultation) of a dental surgeon, repeated	As needed

\* “1” – if once; “according to the algorithm” – if it is necessary for several times (2 or more); “as needed” – if not necessary (at the discretion of the attending physician)

#### **7.4.6. Characteristics of algorithms and features of performing drug-free assistance**

Drug-free assistance is aimed at eliminating one of the main etiological factors of parodontal diseases – bacterial biofilm and factors that ensure its accumulation. When removing dental deposits, it is a prerequisite to create a clean, biocompatible, smooth root surface by removing destroyed and infected tissues. At this, antiseptics and local antibiotics are considered as additional means. See Appendix №12.

Drug-free assistance also includes surgical, orthopedic and orthodontic treatment.

For the treatment of localized periodontitis of moderate severity, as a rule, it is required to manufacture temporary and/or fixed removable and non-removable orthopedic structures, the choice of which depends on the state of the hard dental tissues in the focus of inflammation, the presence of defects in the dentition and the data of the odontoparodontogram according to V. Yu. Kurlandsky and other additional examination methods. See appendices №7, №11, №14, №15.

#### **7.4.7. Requirements for pharmaceutical outpatient medical care**

Name of the group	Frequency (duration of treatment)
Antimicrobials for local treatment of oral diseases	According to the algorithm
Preparations for local anesthesia	As needed
Antimicrobials for systemic use	As needed
Nonsteroidal anti-inflammatory drugs;	As needed
Antihistamines	As needed

#### **7.4.8. Characteristics of algorithms and features of the use of pharmaceutical means**

Before performing the manipulations, if medically required, anesthesia is performed (application, infiltration, conductor). Before anesthesia, the injection site is treated with an application anesthetic, if necessary. Additionally, therapeutic toothpastes based on antiseptics and other anti-inflammatory agents are used.

The basis of medical treatment of parodontitis is antiseptics. They are used in the form of oral baths, applications and irrigation. Non-steroidal anti-inflammatory drugs are prescribed to relieve pain and edema.

Antihistamines are prescribed after surgical interventions.

Antimicrobials of systemic action are prescribed for intoxication and complications after surgery.

#### **7.4.9. Requirements for the regime of work, rest, treatment and rehabilitation**

After the treatment, dynamic monitoring is necessary – 2 times during the first year.

A control X-ray examination should be performed at least once a year.

**7.4.10. Requirements for patient care and auxiliary procedures**

There are no special requirements.

**7.4.11. Requirements for dietary prescriptions and restrictions**

After performing surgical manipulations, it is not recommended to take food for two hours. On the day of surgery, it is recommended to avoid eating rough, hot food and not to chew on the operated side.

**7.4.12. The form of the patient's informed voluntary consent when implementing Clinical recommendations (treatment protocols)**

See Appendix № 8.

**7.4.13. Additional information for the patient and his family members**

See Appendix № 9.

**7.4.14. Rules for changing the requirements when implementing Clinical recommendations (treatment protocols) “Parodontitis” and termination of the requirements of Clinical recommendations (treatment protocols)**

If signs requiring preparatory measures for treatment are detected during the process of making the diagnosis, the patient is transferred to Clinical recommendations (treatment protocols) corresponding to the identified diseases and complications.

If signs of another disease requiring diagnostic and therapeutic measures are detected, along with signs of parodontitis, medical care is provided to the patient in accordance with the requirements of:

a) the section of these Clinical recommendations (treatment protocols) corresponding to parodontitis;

b) Clinical recommendations (treatment protocols) with the identified disease or syndrome.

**7.4.15. Possible outcomes and their characteristics**

Name of the outcome	Frequency of development,	Criteria and Signs	Estimated time to	Continuity and phasing
---------------------	---------------------------	--------------------	-------------------	------------------------

	%		reach the outcome	of medical care
Function compensation	70	No inflammation. Reduction of pathological mobility of teeth to 1 degree	After treatment	Dynamic observation 2 times during the first year.
Stabilization	20	Lack of both positive and negative dynamics	After treatment	Dynamic observation 2 times during the first year.
Development of iatrogenic complications	5	The onset of new lesions or leveling in on caused by the therapy (for example, allergic reactions)	At any stage	Provision of medical care according to the protocol of appropriate care
Development of a new disease associated with the underlying medical condition	5	Relapse of periodontitis, its progression	In the absence of supportive parodontal treatment	Provision of medical care according to the protocol of appropriate care

#### **7.4.16. Cost characteristics of Clinical recommendations (treatment protocols) “Parodontitis”**

The cost characteristics are determined according to the requirements of regulatory documents.

#### **7.5. Patient’s Model**

**Nosological form:** localized chronic periodontitis

**Stage:** severe

**Phase:** stable course

**Complication:** no complications.

**ICD-10 code:** K05. 30

### **7.5.1 Criteria and signs that determine the patient's model**

- ✓ patients with permanent teeth
- ✓ a limited lesion area is noted as a consequence of the influence of a particular
- ✓ etiological factor
- ✓ pathological mobility of teeth of 2-3 degrees
- ✓ the depth of periodontal pockets is up to 6 mm
- ✓ unsatisfactory hygiene
- ✓ soft, hard dental deposits
- ✓ the gum is hyperemic, swollen
- ✓ swelling of the gums
- ✓ bleeding gums
- ✓ exposure of the teeth roots
- ✓ displacement of teeth, pronounced traumatic occlusion
- ✓ the presence of exudate from periodontal pockets
- ✓ radiology determines:

expansion of the periodontal fissure, resorption of the tips of the interdental septa to  $1\frac{1}{2}$  of the root length, destruction of the cortical plate.

### **7.5.2. The procedure for including the patient in Clinical recommendations (treatment protocols)**

The patient's condition that meets the criteria and signs of diagnosis of this patient model.

### **7.5.3. Requirements for the outpatient diagnosis**

Code	Name	Frequency of execution
A01. 07.001	Taking the history and complaints in oral pathology	1
A01. 07.005	Visual examination of the maxillofacial region.	1
A01. 07.003	Palpation of the oral organs	1
A02. 07.007	Teeth percussion	1
A02. 07.005	Thermodiagnosis of the tooth	As needed

A02. 07.008	Determination of the degree of tooth mobility.	According to the algorithm
A02. 07.006	Occlusion detection	According to the algorithm
A02. 07.003	Examination of parodontal pockets using a periodontal probe	According to the algorithm
A12. 07.002	Computer diagnostics of parodontal diseases using electronic probing devices	As needed
A12. 07.001	Vital staining of hard dental tissues	According to the algorithm
A12. 07.003	Determination of oral hygiene indices	According to the algorithm
A12. 07.004	Determination of parodontal indices	According to the algorithm
A02. 07.001	Oral examination with the help of additional tools	1
A05. 07.001	Electrodontometry	As needed
A03. 07.003	Diagnostics of the dento-facial system using methods and means of radiation imaging	As needed
A06.07.003	Targeted intraoral contact radiography	As needed
A06.07.004	Orthopantomography	1
A06. 07.007	Intraoral radiography in occlusion	As needed
A06.31.006	Description and interpretation of radiographic images	As needed
A06.07.010	Palpation of the maxillofacial region.	As needed
A09. 07.002	Cytological examination of the cyst (abscess) contents of the oral cavity or the contents of a dental pocket	As needed
A09.07.005	Microscopic examination of the discharge from the mouth for sensitivity to antibacterial and antifungal agents	As needed
B01. 065. 01	Attendance (examination, consultation) of a dentist therapist, primary	1
B01. 066. 01	Attendance (examination, consultation) of a dentist orthopedist, primary	1
B01. 067. 01	Attendance (examination, consultation) of a dental surgeon, primary	As needed
B01.063.001	Attendance (examination, consultation) of a dental orthodontist, primary	As needed

B01.054.001	Examination (consultation) of a physiotherapist	As needed
-------------	--	-----------

\* “1” – if once; “according to the algorithm” – if it is necessary to do several times (2 or more); “as needed” – if it is not necessary (at the discretion of the attending physician)

#### **7.5.4. Characteristics of algorithms and features of performing diagnostic measures**

Diagnostics is aimed at making the diagnosis that corresponds to the patient’s model, excluding complications, determining the opportunity to start treatment without additional diagnostic and therapeutic and preventive measures.

For this purpose, all patients by all means undergo taking their history, an examination of the mouth and teeth, as well as other necessary examinations, the results of which are entered in the medical card of the dental patient (form 043/y).

#### **Taking the history**

When taking the history, complaints and the timing of their onset are found out. As a rule, the patient complains of pain from all types of irritants and / or spontaneous; bleeding of the gums when brushing teeth, during meals or spontaneous; localized mobility of the teeth and their displacement, bad breath, defects in fillings and orthopedic structures, aesthetic discomfort. It is specified how many years the patient has been suffering from this disease or when the first symptoms appeared, whether he was treated earlier for this disease, the nature of the treatment, its volume (according to the patient) is found out, the result (sustained improvement, temporary improvement, without improvement or deterioration).

The presence of general somatic diseases in the patient, his allergic history are identified. The dentist finds out whether the patient performs proper hygienic care of the mouth.

Visual examination, external examination of the maxillofacial area, examination with additional tools.

When examining the maxillofacial region, the presence of visible changes is noted, the lymph nodes of the head and neck are palpated bimanually and bilaterally, comparing the right and left halves.

When examining the mouth, the condition of the dentition, the mucous membrane of the mouth and throat, its color, moisture content, the presence of pathological changes are evaluated. Special attention is paid to the depth of the vestibule, the nature of the lingual frenulum and the labial frenulum attachment, strands of the mucous membrane in the vestibule of the mouth. The dentist determines the state of occlusion, anomalies in the position of individual teeth, as well as the dentition as a whole, the presence of tremas, diastemas.

The dentist also determines the condition of the mucous membrane, its color, the degree of edema, the degree of moisture, the nature of saliva.

Assessment of periodontal tissues condition is carried out by probing using a periodontal probe (as well as electronic probing devices). At this, the presence of bleeding gums, the depth of the periodontal pocket, the magnitude of the gum recession, the presence of dental deposits and their nature, the presence of a discharge from the periodontal pocket are evaluated. Probing of the periodontal pocket is carried out at 6 points of each tooth (121eleveling121-distal, vestibular, 121eleveling121-medial, lingual-distal, lingual and lingual-medial). In multi-root teeth, the presence of furcation defects and their class are evaluated using a furcation probe. See Appendices №4, №10.

Tooth mobility is an important metric criterion for assessing the condition of parodontal tissues. When planning treatment, examination of dental mobility is a mandatory diagnostic measure. When assessing teeth mobility, the most common is Entin classification, as well as Miller classification and Flezar modification. See Appendix №3

Occlusal contacts are evaluated using articulation paper, wax plates and / or electronic devices.

Special attention is paid to the identification of improperly manufactured fillings, the functional state of existing orthopedic structures (removable and non-removable), orthodontic devices, as well as the correct care of prostheses.

On the basis of clinical and additional methods of examination, an odontoparodontogram is filled in according to V. Yu. Kurlandsky. See Appendix №16.

When assessing the level of hygiene, attention is paid to the patient's hygiene skills in mouth care: when, how many times a day he brushes his

teeth, the method of cleaning, which pastes and brushes he uses, how often he changes them. Dental plaque indicators and hygiene indices are used to control the quality of tooth brushing. In addition to hygiene indices, the bleeding index is calculated to determine the degree of gum inflammation. See Appendices №2, №6.

As additional methods of examination, methods of X-ray diagnostics, microbiological and cytological studies, etc. are used.

At the end of the examination, which is carried out jointly with dental surgeons, orthopedic dentists, orthodontists, a comprehensive treatment plan is drawn up.

### 7.5.5. Requirements for the outpatient treatment

Code	Name	Frequency of execution
A14. 07. 003	Oral hygiene	According to the algorithm
A16.07.055	Professional oral and dental hygiene	According to the algorithm
A13.31.007	Training in oral hygiene.	According to the algorithm
A14. 07. 004	Controlled brushing of teeth	According to the algorithm
B01.003.004.001	Local anesthesia	As needed
A 22.07.002	Ultrasound removal of supra-gingival and subgingival dental deposits	As needed
A 16.07.022	Removal of supra-gingival and subgingival dental deposits	According to the algorithm
A22. 07. 001	Ultrasound treatment of periodontal pockets	As needed
A16. 07. 043	Closed curettage for parodontal diseases	According to the algorithm
A 16.07.001	Tooth extraction	As needed
A16.07.021	Temporary splinting in parodontal diseases	As needed
A16.07.029	Algorithm of selective grinding of hard dental tissues	According to the algorithm
A16.07.048	Frenuloplasty	As needed
A16.07.046	Plastic surgery of the upper lip frenulum	As needed

A16.07.047	Plastic surgery of the lower lip frenulum	As needed
A16.07.049	Vestibuloplasty	As needed
A16.07.044	Flap surgery	As needed
A16.07.002	Tooth restoration with a filling	As needed
A16.07.004	Tooth restoration with a crown	As needed
A16.07.005	Restoration of the dentition integrity with fixed bridge prosthesis	As needed
A16.07. 039	Prosthetics with partial removable laminar dentures	As needed
A16.07.00	Prosthetics with removable clasp prostheses	As needed
A16.07.057	Removal of a fixed orthopedic structure	As needed
A16.07. 038	Restoration of the dentition integrity with removable bridge prosthesis	As needed
A16.07.057	Removal of a fixed orthopedic structure	As needed
A17.07.002	Physiotherapy effect on the maxillofacial area	As needed
A16.07.053	Re-fixation of fixed orthopedic structures on permanent cement	As needed
A16.07.041	Permanent splinting with solid-cast removable structures for parodontal diseases	As needed
A25.07.001	Prescription of drug therapy for diseases of the mouth and teeth	As needed
B01.065.02	Attendance (examination, consultation) of a dentist therapist, repeated	1
B01.066.02	Attendance (examination, consultation) of a dentist orthopedist, repeated	1
B01. 067. 02	Attendance (examination, consultation) of a dental surgeon, repeated	As needed

\* “1” – if once; “according to the algorithm” – if it is necessary to do several times (2 or more); “as needed” – if it is not necessary (at the discretion of the attending physician)

### **7.5.6. Characteristics of algorithms and features of performing drug-free assistance**

Drug-free assistance is aimed at eliminating one of the main etiological factors of parodontal diseases – bacterial biofilm and factors that ensure its accumulation. When removing dental deposits, it is a prerequisite to create a clean, biocompatible, smooth root surface by removing destroyed and infected tissues. At this, antiseptics and local antibiotics are considered as additional means. See Appendix №12.

Drug-free assistance also includes surgical, orthopedic and orthodontic treatment. To treat localized periodontitis of severe severity, as a rule, it is necessary to manufacture temporary and / or permanent removable and

fixed orthopedic structures, the choice of which depends on the state of the hard tissues of the teeth in the focus of inflammation, the presence of defects in the dentition and the data of the odontoparodontogram according to V. Yu. Kurlandsky and other additional examination methods. See appendices №7, №11, №14, №15.

### **7.5.7. Requirements for pharmaceutical outpatient medical care**

Name of the group	Frequency (duration of treatment)
Antimicrobials for local treatment of oral diseases	According to the algorithm
Preparations for local anesthesia	As needed
Antimicrobials for systemic use	As needed
Nonsteroidal anti-inflammatory drugs;	As needed
Antihistamines	As needed

### **7.5.8. Characteristics of algorithms and features of the use of pharmaceutical means**

Before performing manipulations, if medically required, anesthesia is performed (application, infiltration, conductor), before anesthesia, the injection site is treated with an application anesthetic, if necessary. Additionally, therapeutic toothpastes based on antiseptics and other anti-inflammatory agents are used.

The basis of medical treatment of parodontitis is antiseptics. They are used in the form of oral baths, applications and irrigation. Non-

steroidal anti-inflammatory drugs are prescribed to relieve pain and edema.

Antihistamines are prescribed after surgical interventions.

Antimicrobials of systemic action are prescribed for intoxication and complications after surgery.

#### **7.5.9. Requirements for the regime of work, rest, treatment and rehabilitation**

After the treatment, dynamic monitoring is necessary – 4 times during the first year.

A control X-ray examination should be performed twice a year.

#### **7.5.10. Requirements for patient care and auxiliary procedures**

There are no special requirements.

#### **7.5.11. Requirements for dietary prescriptions and restrictions**

After performing surgical manipulations, it is not recommended to take food for two hours. On the day of surgery, it is recommended to avoid eating rough, hot food and not to chew on the operated side.

#### **7.5.12. The form of the patient's informed voluntary consent when performing the protocol**

See Appendix № 8.

#### **7.5.13. Additional information for the patient and his family members**

See Appendix № 9.

#### **7.5.14. Rules for changing the requirements when implementing Clinical recommendations (treatment protocols) “Parodontitis” and termination of the requirements of Clinical recommendations (treatment protocols)**

If signs requiring preparatory measures for treatment are detected during the process of making the diagnosis, the patient is transferred to Clinical recommendations (treatment protocols) corresponding to the identified diseases and complications.

If signs of another disease requiring diagnostic and therapeutic measures are detected, along with signs of parodontitis, medical care is provided to the patient in accordance with the requirements of:

- a) the section of these Clinical recommendations (treatment protocols) corresponding to localized parodontitis;
- b) Clinical recommendations (treatment protocols) with the identified disease or syndrome.

#### **7.5.15. Possible outcomes and their characteristics**

Name of the outcome	Frequency of development, %	Criteria and Signs	Estimated time to reach the outcome	Continuity and phasing of medical care
Function compensation	65	No inflammation. Reduction of pathological mobility of teeth to 1-2 degree	After treatment	Dynamic observation 4 times during a year.
Stabilization	25	Lack of both positive and negative dynamics	After treatment	Dynamic observation 4 times during a year.
Development of iatrogenic complications	5	The onset of new lesions or leveling caused by the therapy (for example, allergic reactions)	At any stage	Provision of medical care according to the protocol of appropriate care
Development of a new disease associated with the underlying medical	5	Relapse of periodontitis, its progression	In the absence of supportive parodontal treatment	Provision of medical care according to the protocol of appropriate

condition				care
-----------	--	--	--	------

### **7.5.16. Cost characteristics of Clinical recommendations (treatment protocols)**

The cost characteristics are determined according to the requirements of regulatory documents.

### **7.6. Patient's Model**

**Nosological form:** generalized chronic periodontitis

**Stage:** mild

**Phase:** stable course

**Complication:** no complications.

**ICD-10 code:** K05. 30

#### **7.6.1 Criteria and signs that determine the patient's model**

- ✓ patients with permanent teeth
- ✓ the pathological process involves periodontal tissues of most of the teeth on one or both jaws
- ✓ pathological mobility of teeth of the 1<sup>st</sup> degree
- ✓ the depth of periodontal pockets is up to 4 mm
- ✓ there is an unpleasant smell from the mouth
- ✓ a history of bleeding gums
- ✓ unsatisfactory hygiene
- ✓ soft, hard dental deposits
- ✓ the gum is hyperemic and / or cyanotic
- ✓ there is swelling of the gingival crest
- ✓ there is bleeding of the gums during probing
- ✓ radiology determines:

expansion of the periodontal fissure, resorption of the tips of the interdental septa to  $\frac{1}{3}$  of the root length, destruction of the cortical plate.

#### **7.6.2. The procedure for including the patient in Clinical recommendations (treatment protocols)**

The patient's condition that meets the criteria and signs of diagnosis of this patient model.

### 7.6.3. Requirements for the outpatient diagnosis

Code	Name	Frequency of execution
A01. 07.002	Visual examination in oral pathology	1
A01. 07.003	Palpation of the oral organs	1
A01.07.004	Percussion in oral pathology	1
A01. 07.005	Visual examination of the maxillofacial region.	1
A02. 07.001	Oral examination with the help of additional tools	1
A02. 07.003	Examination of parodontal pockets using a periodontal probe	According to the algorithm
A02. 07.005	Thermodiagnosis of the tooth	As needed
A12. 07.001	Vital staining of hard dental tissues	According to the algorithm
A12. 07.003	Determination of oral hygiene indices	According to the algorithm
A12. 07.004	Determination of parodontal indices	According to the algorithm
A02. 07.006	Occlusion detection	According to the algorithm
A02. 07.007	Teeth percussion	As needed
A03. 07.003	Diagnostics of the dento-facial system using methods and means of radiation imaging	As needed
A05. 07.001	Electrodontometry	As needed
A02. 07.008	Determination of the degree of tooth mobility.	According to the algorithm
A12. 07.002	Computer diagnostics of parodontal diseases using electronic probing devices	As needed
A06.07.003	Targeted intraoral contact radiography	As needed
A06.07.004	Orthopantomography	1
A06. 07.007	Intraoral radiography in occlusion	As needed
A06.07.010	Palpation of the maxillofacial region.	As needed
A06.31.006	Description and interpretation of radiographic images	As needed
B01. 065. 01	Attendance (examination, consultation) of a dentist therapist, primary	1
B01. 066.01	Attendance (examination, consultation) of a dentist orthopedist, primary	As needed

B01.067.01	Attendance (examination, consultation) of a dental surgeon, primary	As needed
B01.063.001	Attendance (examination, consultation) of a dental orthodontist, primary	As needed
B01.054.001	Examination (consultation) of a physiotherapist	As needed

\* “1” – if once; “according to the algorithm” – if it is necessary to do several times (2 or more); “as needed” – if it is not necessary (at the discretion of the attending physician)

#### **7.6.4. Characteristics of algorithms and features of performing diagnostic measures**

Diagnostics is aimed at making the diagnosis that corresponds to the patient’s model, excluding complications, determining the opportunity to start treatment without additional diagnostic and therapeutic and preventive measures.

For this purpose, all patients by all means undergo taking their history, an examination of the mouth and teeth, as well as other necessary examinations, the results of which are entered in the medical card of the dental patient (form 043/y).

##### **Taking the history**

When taking the history, complaints and the timing of their onset are found out. As a rule, the patient complains of pain from all types of irritants and / or spontaneous one; bleeding of the gums when brushing teeth, during meals or spontaneous; localized mobility of the teeth and their displacement, bad breath, defects in fillings and orthopedic structures, aesthetic discomfort. It is specified how many years the patient has been suffering from this disease or when the first symptoms appeared, whether he was treated earlier for this disease, the nature of the treatment, its volume (according to the patient) is found out, the result (sustained improvement, temporary improvement, without improvement or deterioration).

The presence of general somatic diseases in the patient, his allergic history are identified. The dentist finds out whether the patient performs proper hygienic care of the mouth.

Visual examination, external examination of the maxillofacial region, examination with the help of additional instruments When examining the maxillofacial region, the presence of visible changes is

noted, the lymph nodes of the head and neck are palpated bimanually and bilaterally, comparing the right and left halves.

When examining the mouth, the condition of the dentition, the mucous membrane of the mouth and throat, its color, moisture content, the presence of pathological changes are evaluated. Special attention is paid to the depth of the vestibule, the nature of the lingual frenulum and the labial frenulum attachment, strands of the mucous membrane in the vestibule of the mouth. The dentist determines the state of occlusion, anomalies in the position of individual teeth, as well as the dentition as a whole, the presence of tremas, diastemas.

The dentist also determines the condition of the mucous membrane, its color, the degree of edema, the degree of moisture, the nature of saliva.

Assessment of periodontal tissues condition is carried out by probing using a periodontal probe (as well as electronic probing devices). At this, the presence of bleeding gums, the depth of the periodontal pocket, the magnitude of the gum recession, the presence of dental deposits and their nature, the presence of a discharge from the periodontal pocket are evaluated. Probing of the periodontal pocket is carried out at 6 points of each tooth (130eleveling130-distal, vestibular, 130eleveling130-medial, lingual-distal, lingual and lingual-medial). In multi-root teeth, the presence of furcation defects and their class are evaluated using a furcation probe. See Appendices №4, №10.

Tooth mobility is an important metric criterion for assessing the condition of parodontal tissues. When planning treatment, examination of dental mobility is a mandatory diagnostic measure. When assessing teeth mobility, the most common is Entin classification, as well as Miller classification and Flezar modification. See Appendix №3

Occlusal contacts are evaluated using articulation paper, wax plates and / or electronic devices.

Special attention is paid to identification of improperly manufactured fillings, the functional state of existing orthopedic structures (removable and non-removable), orthodontic devices, as well as the correct care of prostheses.

On the basis of clinical and additional methods of examination, an odontoparodontogram is filled in according to V. Yu. Kurlandsky. See Appendix №16.

When assessing the level of hygiene, attention is paid to the patient's hygiene skills in mouth care: when, how many times a day he brushes his teeth, the method of cleaning, which pastes and brushes he uses, how often he changes them. Dental plaque indicators and hygiene indices are used to control the quality of tooth brushing. In addition to hygiene indices, the bleeding index is calculated to determine the degree of gum inflammation. See Appendices №2, №6.

As additional methods of examination, methods of X-ray diagnostics, microbiological and cytological studies, etc. are used.

At the end of the examination, which is carried out jointly with dental surgeons, orthopedic dentists, orthodontists, a comprehensive treatment plan is drawn up.

#### **7.6.5. Requirements for the outpatient treatment**

Code	Name	Frequency of execution
A14. 07. 003	Oral hygiene	According to the algorithm
A16.07.055	Professional oral and dental hygiene	According to the algorithm
A13.31.007	Training in oral hygiene.	According to the algorithm
A14. 07. 004	Controlled brushing of teeth	According to the algorithm
B01.003.004.001	Local anesthesia	As needed
A22.07.002	Ultrasound removal of supra-gingival and subgingival dental deposits	As needed
A16.07.022	Removal of supra-gingival and subgingival dental deposits	According to the algorithm
A22. 07. 001	Ultrasound treatment of periodontal pockets	According to the algorithm
A16. 07. 043	Closed curettage for parodontal diseases	As needed
A16.07.021	Temporary splinting in parodontal diseases	As needed
A16.07.029	Algorithm of selective grinding of hard dental tissues	As needed
A16.07.030	Gingivectomy.	As needed

A16.07.048	Frenuloplasty	As needed
A16.07.046	Plastic surgery of the upper lip frenulum	As needed
A16.07.047	Plastic surgery of the lower lip frenulum	As needed
A16.07.049	Vestibuloplasty	As needed
A16.07.005	Restoration of the dentition integrity with fixed bridge prosthesis	As needed
A16.07.039	Prosthetics with partial removable laminar dentures	As needed
A16.07.038	Restoration of the dentition integrity with removable bridge prosthesis	As needed
A16.07.057	Removal of a fixed orthopedic structure	As needed
A17.07.002	Physiotherapy effect on the maxillofacial area	As needed
A16.07.057	Removal of a fixed orthopedic structure	As needed
A16.07.053	Re-fixation of fixed orthopedic structures on permanent cement	As needed
A25.07.001	Prescription of drug therapy for diseases of the mouth and teeth	As needed
B01.065.02	Attendance (examination, consultation) of a dentist therapist, repeated	As needed
B01.066.02	Attendance (examination, consultation) of a dentist orthopedist, repeated	As needed
B01.067.02	Attendance (examination, consultation) of a dental surgeon, repeated	As needed

\* “1” – if once; “according to the algorithm” – if it is necessary to do several times (2 or more); “as needed” – if it is not necessary (at the discretion of the attending physician)

### **7.6.6. Characteristics of algorithms and features of performing drug-free assistance**

Drug-free assistance is aimed at eliminating one of the main etiological factors of parodontal diseases – bacterial biofilm and factors that ensure its accumulation. When removing dental deposits, it is a

prerequisite to create a clean, biocompatible, smooth root surface by removing destroyed and infected tissues. See Appendix №12.

Drug-free assistance also includes surgical, orthopedic and orthodontic treatment. See Appendices №7, №11, №14, №15.

#### **7.6.7. Requirements for pharmaceutical outpatient medical care**

Name of the group	Frequency (duration of treatment)
Antimicrobials for local treatment of oral diseases	According to the algorithm
Preparations for local anesthesia	As needed
Antimicrobials for systemic use	As needed
Nonsteroidal anti-inflammatory drugs;	As needed
Antihistamines	As needed

#### **7.6.8. Characteristics of algorithms and features of the use of pharmaceutical means**

Before performing manipulations, if medically required, anesthesia is performed (application, infiltration, conductor), before anesthesia, the injection site is treated with an application anesthetic, if necessary. Additionally, therapeutic toothpastes based on antiseptics and other anti-inflammatory agents are used.

The basis of medical treatment of parodontitis is antiseptics. They are used in the form of oral baths, applications and irrigation. Non-steroidal anti-inflammatory drugs are prescribed to relieve pain and edema.

Antihistamines are prescribed after surgical interventions.

Antimicrobials of systemic action are prescribed for intoxication and complications after surgery.

#### **7.6.9. Requirements for the regime of work, rest, treatment and rehabilitation**

After the treatment, dynamic monitoring is necessary – 2 times during the first year. Later, once a year with a control radiography.

#### **7.6.10. Requirements for patient care and auxiliary procedures**

Detailed recommendations are given in the algorithms for each type of intervention.

#### **7.6.11. Requirements for dietary prescriptions and restrictions**

After performing surgical manipulations, it is not recommended to take food for two hours. On the day of surgery, it is recommended to avoid eating rough, hot food and not to chew on the operated side, not to warm it. Not to overheat the body. Exclude physical activity.

#### **7.6.12. The form of the patient's informed voluntary consent when implementing Clinical recommendations (treatment protocols) "Parodontitis"**

See Appendix № 8.

#### **7.6.13. Additional information for the patient and his family members**

See Appendix № 9.

#### **7.6.14. Rules for changing the requirements when implementing Clinical recommendations (treatment protocols) "Parodontitis" and termination of the requirements of Clinical recommendations (treatment protocols)**

If signs requiring preparatory measures for treatment are detected during the process of making the diagnosis, the patient is transferred to Clinical recommendations (treatment protocols) corresponding to the identified diseases and complications.

If signs of another disease requiring diagnostic and therapeutic measures are detected, along with signs of parodontitis, medical care is provided to the patient in accordance with the requirements of:

- a) the section of these Clinical recommendations (treatment protocols) corresponding to parodontitis;
- b) Clinical recommendations (treatment protocols) with the identified disease or syndrome.

#### **7.6.15. Possible outcomes and their characteristics**

Name of the outcome	Frequency of development, %	Criteria and Signs	Estimated time to reach the	Continuity and phasing of medical
---------------------	-----------------------------	--------------------	-----------------------------	-----------------------------------

			outcome	care
Function compensation	80	Restoration of the gums appearance, the absence of signs of inflammation	In 7 days	Dynamic observation 2 times during the first year. Later, once a year.
Stabilization	10	Lack of both positive and negative dynamics	In 7 days	Dynamic observation 2 times during the first year. Later, once a year.
Development of iatrogenic complications	5	The onset of new lesions or leveling of lesions caused by the therapy (for example, allergic reactions)	At any stage	Provision of medical care according to the protocol of appropriate care
Development of a new disease associated with the underlying medical condition	5	Relapse of periodontitis, its progression	In the absence of supportive parodontal treatment	Provision of medical care according to the protocol of appropriate care

#### **7.6.16. Cost characteristics of Clinical recommendations (treatment protocols) “Parodontitis”**

The cost characteristics are determined according to the requirements of regulatory documents.

#### **7.7. Patient’s Model**

**Nosological form:** generalized chronic periodontitis

**Stage:** Moderate

**Phase:** stable course

**Complication:** no complications.

**ICD-10 code:** K05. 30

### **7.7.1 Criteria and signs that determine the patient's model**

- ✓ patients with permanent teeth
- ✓ the pathological process involves periodontal tissues of most of the teeth on one or both jaws
- ✓ pathological mobility of teeth of the 2<sup>nd</sup> degree
- ✓ the depth of periodontal pockets is up to 6 mm
- ✓ there is an unpleasant smell from the mouth, the medical history contains bleeding gums
- ✓ unsatisfactory hygiene
- ✓ soft, hard dental deposits
- ✓ the gum is hyperemic and / or cyanotic
- ✓ there is swelling of the gingival crest
- ✓ there is bleeding of the gums during probing
- ✓ exposure of the teeth roots
- ✓ radiology determines:

expansion of the periodontal fissure, resorption of the tips of alveolar walls to 1\2 of the root length, destruction of the cortical plate.

### **7.7.2. The procedure for including the patient in Clinical recommendations (treatment protocols)**

The patient's condition that meets the criteria and signs of diagnosis of this patient model.

### **7.7.3. Requirements for the outpatient diagnosis**

Code	Name	Frequency of execution
A01. 07.002	Visual examination in oral pathology	1
A01. 07.003	Palpation of the oral organs	1
A01.07.004	Percussion in oral pathology	1
A01. 07.005	Visual examination of the maxillofacial region.	1
A02. 07.001	Oral examination with the help of additional tools	1
A02. 07.003	Examination of parodontal pockets	According to

	using a periodontal probe	the algorithm
A02. 07.005	Thermodiagnosis of the tooth	As needed
A12. 07.001	Vital staining of hard dental tissues	According to the algorithm
A12. 07.003	Determination of oral hygiene indices	According to the algorithm
A12. 07.004	Determination of parodontal indices	According to the algorithm
A02. 07.006	Occlusion detection	According to the algorithm
A02. 07.007	Teeth percussion	As needed
A03. 07.003	Diagnostics of the dento-facial system using methods and means of radiation imaging	As needed
A05. 07.001	Electrodontometry	As needed
A02. 07.008	Determination of the degree of tooth mobility.	According to the algorithm
A12. 07.002	Computer diagnostics of parodontal diseases using electronic probing devices	As needed
A06.07.003	Targeted intraoral contact radiography	As needed
A06.07.004	Orthopantomography	1
A06. 07.007	Intraoral radiography in occlusion	As needed
A06.07.010	Palpation of the maxillofacial region.	As needed
A06.31.006	Description and interpretation of radiographic images	As needed
B01. 066. 01	Attendance (examination, consultation) of a dentist orthopedist, primary	1
B01. 065. 01	Attendance (examination, consultation) of a dentist therapist, primary	1
B01. 067. 01	Attendance (examination, consultation) of a dental surgeon, primary	As needed
B01.063.001	Attendance (examination, consultation) of a dental orthodontist, primary	As needed
B01.054.001	Examination (consultation) of a physiotherapist	As needed

\* "1" – if once; "according to the algorithm" – if it is necessary to do several times (2 or more); "as needed" – if it is not necessary (at the discretion of the attending physician)

#### **7.7.4. Characteristics of algorithms and features of performing diagnostic measures**

Diagnostics is aimed at making the diagnosis that corresponds to the patient's model, excluding complications, determining the opportunity to start treatment without additional diagnostic and therapeutic and preventive measures.

For this purpose, all patients by all means undergo taking their history, an examination of the mouth and teeth, as well as other necessary examinations, the results of which are entered in the medical card of the dental patient (form 043/y).

##### **Taking the history**

When taking the history, complaints and the timing of their onset are found out. As a rule, the patient complains of pain from all types of irritants and / or spontaneous one; bleeding of the gums when brushing teeth, during meals or spontaneous; localized mobility of the teeth and their displacement, bad breath, defects in fillings and orthopedic structures, aesthetic discomfort. It is specified how many years the patient has been suffering from this disease or when the first symptoms appeared, whether he was treated earlier for this disease, the nature of the treatment, its volume (according to the patient) is found out, the result (sustained improvement, temporary improvement, without improvement or deterioration).

The presence of general somatic diseases in the patient, his allergic history are identified. The dentist finds out whether the patient performs proper hygienic care of the mouth.

Visual examination, external examination of the maxillofacial area, examination with additional tools.

When examining the maxillofacial region, the presence of visible changes is noted, the lymph nodes of the head and neck are palpated bimanually and bilaterally, comparing the right and left halves.

When examining the mouth, the condition of the dentition, the mucous membrane of the mouth and throat, its color, moisture content, the presence of pathological changes are evaluated. Special attention is paid to the depth of the vestibule, the nature of the lingual frenulum and the labial frenulum attachment, strands of the mucous membrane in the vestibule of the mouth. The dentist determines the state of occlusion,

anomalies in the position of individual teeth, as well as the dentition as a whole, the presence of tremas, diastemas.

The dentist also determines the condition of the mucous membrane, its color, the degree of edema, the degree of moisture, the nature of saliva.

Assessment of periodontal tissues condition is carried out by probing using a periodontal probe (as well as electronic probing devices). At this, the presence of bleeding gums, the depth of the periodontal pocket, the magnitude of the gum recession, the presence of dental deposits and their nature, the presence of a discharge from the periodontal pocket are evaluated. Probing of the periodontal pocket is carried out at 6 points of each tooth (139eveling139-distal, vestibular, 139eveling139-medial, lingual-distal, lingual and lingual-medial). In multi-root teeth, the presence of furcation defects and their class are evaluated using a furcation probe. See Appendices №4, №10.

Tooth mobility is an important metric criterion for assessing the condition of parodontal tissues. When planning treatment, examination of dental mobility is a mandatory diagnostic measure. When assessing teeth mobility, the most common is Entin classification, as well as Miller classification and Flezar modification. See Appendix №3

Occlusal contacts are evaluated using articulation paper, wax plates and / or electronic devices.

Special attention is paid to identification of improperly manufactured fillings, the functional state of existing orthopedic structures (removable and non-removable), orthodontic devices, as well as the correct care of prostheses.

On the basis of clinical and additional methods of examination, an odontoparodontogram is filled in according to V. Yu. Kurlandsky. See Appendix №16. When assessing the level of hygiene, attention is paid to the patient's hygiene skills in mouth care: when, how many times a day he brushes his teeth, the method of cleaning, which pastes and brushes he uses, how often he changes them. Dental plaque indicators and hygiene indices are used to control the quality of tooth brushing. In addition to hygiene indices, the bleeding index is calculated to determine the degree of gum inflammation. See Appendices №2, №6.

As additional methods of examination, methods of X-ray diagnostics, microbiological and cytological studies, etc. are used.

At the end of the examination, which is carried out jointly with dental surgeons, orthopedic dentists, orthodontists, a comprehensive treatment plan is drawn up.

**7.7.5. Requirements for the outpatient treatment**

Code	Name	Frequency of execution
A14. 07. 003	Oral hygiene	According to the algorithm
A16.07.055	Professional oral and dental hygiene	According to the algorithm
A13.31.007	Training in oral hygiene.	According to the algorithm
A14. 07. 004	Controlled brushing of teeth	According to the algorithm
B01.003.004.001	Local anesthesia	As needed
A22.07.002	Ultrasound removal of supra-gingival and subgingival dental deposits	As needed
A16.07.022	Removal of supra-gingival and subgingival dental deposits	According to the algorithm
A22. 07. 001	Ultrasound treatment of periodontal pockets	According to the algorithm
A16. 07. 043	Closed curettage for parodontal diseases	According to the algorithm
A16.07.001	Tooth extraction	As needed
A16.07.021	Temporary splinting in parodontal diseases	As needed
A16.07.029	Algorithm of selective grinding of hard dental tissues	According to the algorithm
A16.07.030	Gingivectomy.	As needed
A16.07.048	Frenuloplasty	As needed
A16.07.046	Plastic surgery of the upper lip frenulum	As needed
A16.07.047	Plastic surgery of the lower lip frenulum	As needed
A16.07.049	Vestibuloplasty	As needed
A16.07.044	Flap surgery	As needed
A16.07.064	Coronary-radicular separation	As needed
A16.07.063	Hemisection	As needed

A16.07.002	Tooth restoration with a filling	As needed
A16.07.003	Restoration of the tooth with inlays, veneers, a three-quarter crown	As needed
A16.07.004	Tooth restoration with a crown	As needed
A16.07.005	Restoration of the dentition integrity with fixed bridge prosthesis	As needed
A16.07.039	Prosthetics with partial removable laminar dentures	As needed
A16.07.006	Prosthetics of teeth using implants	As needed
A16.07.038	Restoration of the dentition integrity with removable bridge prosthesis	As needed
A16.07.040	Prosthetics with removable clasp prostheses	As needed
A17.07.002	Physiotherapy effect on the maxillofacial area	As needed
A17.07.003	Diathermocoagulation in the pathology of the mouth and teeth	As needed
A16.07.057	Removal of a fixed orthopedic structure	As needed
A16.07.053	Re-fixation of fixed orthopedic structures on permanent cement	As needed
A16.07.041	Permanent splinting with solid-cast removable structures for parodontal diseases	As needed
A25.07.001	Prescription of drug therapy for diseases of the mouth and teeth	As needed
B01.065.02	Attendance (examination, consultation) of a dentist therapist, repeated	As needed
B01.066.02	Attendance (examination, consultation) of a dentist orthopedist, repeated	As needed
B01.067.02	Attendance (examination, consultation) of a dental surgeon, repeated	As needed

\* “1” – if once; “according to the algorithm” – if it is necessary to do several times (2 or more); “as needed” – if it is not necessary (at the discretion of the attending physician)

### **7.7.6. Characteristics of algorithms and features of performing drug-free assistance**

Drug-free assistance is aimed at eliminating one of the main etiological factors of parodontal diseases – bacterial biofilm and factors that ensure its accumulation. When removing dental deposits, it is a prerequisite to create a clean, biocompatible, smooth root surface by removing destroyed and infected tissues. At this, antiseptics and local antibiotics are considered as additional means. See Appendix №12.

Drug-free assistance also includes surgical, orthopedic and orthodontic treatment. To treat generalized periodontitis of moderate severity, as a rule, it is necessary to manufacture temporary and / or permanent removable and

fixed orthopedic structures, the choice of which depends on the state of the hard tissues of the teeth in the focus of inflammation, the presence of defects in the dentition and the data of the odontoparodontogram according to V. Yu. Kurlandsky and other additional examination methods. See appendices №7, №11, №14, №15.

#### **7.7.7. Requirements for pharmaceutical outpatient medical care**

Name of the group	Frequency (duration of treatment)
Antimicrobials for local treatment of oral diseases	According to the algorithm
Preparations for local anesthesia	As needed
Antimicrobials for systemic use	As needed
Nonsteroidal anti-inflammatory drugs;	As needed
Antihistamines	As needed

#### **7.7.8. Characteristics of algorithms and features of the use of pharmaceutical means**

Before performing manipulations, if medically required, anesthesia is performed (application, infiltration, conductor), before anesthesia, the injection site is treated with an application anesthetic, if necessary. Additionally, therapeutic toothpastes based on antiseptics and other anti-inflammatory agents are used.

The basis of medical treatment of parodontitis is antiseptics. They are used in the form of oral baths, applications and irrigation. Non-steroidal anti-inflammatory drugs are prescribed to relieve pain and edema.

Antihistamines are prescribed after surgical interventions.

Antimicrobials of systemic action are prescribed for intoxication and complications after surgery.

#### **7.7.9. Requirements for the regime of work, rest, treatment and rehabilitation**

After the treatment, dynamic monitoring is necessary – 2 times during the first year.

A control X-ray examination should be performed at least once a year.

#### **7.7.10. Requirements for patient care and auxiliary procedures**

There are no special requirements.

#### **7.7.11. Requirements for dietary prescriptions and restrictions**

After performing surgical manipulations, it is not recommended to take food for two hours. On the day of surgery, it is recommended to avoid eating rough, hot food and not to chew on the operated side.

#### **7.7.12. The form of the patient's informed voluntary consent when implementing Clinical recommendations (treatment protocols)**

See Appendix № 8.

#### **7.7.13. Additional information for the patient and his family members**

See Appendix № 9.

#### **7.7.14. Rules for changing the requirements when implementing Clinical recommendations (treatment protocols) “Parodontitis” and termination of the requirements of Clinical recommendations (treatment protocols)**

If signs requiring preparatory measures for treatment are detected during the process of making the diagnosis, the patient is transferred to Clinical recommendations (treatment protocols) corresponding to the identified diseases and complications.

If signs of another disease requiring diagnostic and therapeutic measures are detected, along with signs of parodontitis, medical care is provided to the patient in accordance with the requirements of:

- a) the section of these Clinical recommendations (treatment protocols) corresponding to parodontitis;
- b) Clinical recommendations (treatment protocols) with the identified disease or syndrome.

**7.7.15. Possible outcomes and their characteristics**

Name of the outcome	Frequency of development, %	Criteria and Signs	Estimated time to reach the outcome	Continuity and phasing of medical care
Function compensation	60	No inflammation. Reduction of pathological mobility of teeth to 1-2 degree	After treatment	Dynamic follow-up 2 times a year.
Stabilization	30	Lack of both positive and negative dynamics	After treatment	Dynamic follow-up 2 times a year.
Development of iatrogenic complications	5	The onset of new lesions or eveling I on caused by the therapy (for example, allergic reactions)	At any stage	Provision of medical care according to the protocol of appropriate care
Development of a new disease associated with the underlying medical condition	5	Relapse of periodontitis, its progression	In the absence of supportive parodontal treatment	Provision of medical care according to the protocol of appropriate care

**7.7.16. Cost characteristics of Clinical recommendations (treatment protocols) “Parodontitis”**

The cost characteristics are determined according to the requirements of regulatory documents.

### **7.8. Patient's Model**

**Nosological form:** generalized chronic periodontitis

**Stage:** severe

**Phase:** stable course

**Complication:** no complications.

**ICD-10 code:** K05. 30

#### **7.8.1 Criteria and signs that determine the patient's model**

- ✓ patients with permanent teeth
- ✓ the pathological process involves periodontal tissues of most of the teeth on one or both jaws
- ✓ pathological mobility of teeth of 2-3 degrees
- ✓ the depth of periodontal pockets more than 6 mm
- ✓ there is an unpleasant smell from the mouth
- ✓ a history of bleeding gums
- ✓ unsatisfactory hygiene
- ✓ soft, hard dental deposits
- ✓ the gum is hyperemic and / or cyanotic
- ✓ there is swelling of the gingival crest
- ✓ there is bleeding of the gums during probing
- ✓ displacement of teeth.
- ✓ pronounced traumatic occlusion
- ✓ exposure of the teeth roots
- ✓ the presence of exudate from periodontal pockets
- ✓ radiology determines:

expansion of the periodontal fissure, resorption of the bone walls of the alveoli for more than  $1/2$  of the root length.

#### **7.8.2. The procedure for including the patient in Clinical recommendations (treatment protocols)**

The patient's condition that meets the criteria and signs of diagnosis of this patient model.

#### **7.8.3. Requirements for the outpatient diagnosis**

Code	Name	Frequency of execution
A01. 07.002	Visual examination in oral pathology	1
A01. 07.003	Palpation of the oral organs	1
A01.07.004	Percussion in oral pathology	1
A01. 07.005	Visual examination of the maxillofacial region.	1
A02. 07.001	Oral examination with the help of additional tools	1
A02. 07.003	Examination of parodontal pockets using a periodontal probe	According to the algorithm
A02. 07.005	Thermodiagnosis of the tooth	As needed
A12. 07.001	Vital staining of hard dental tissues	According to the algorithm
A12. 07.003	Determination of oral hygiene indices	According to the algorithm
A12. 07.004	Determination of parodontal indices	According to the algorithm
A02. 07.006	Occlusion detection	According to the algorithm
A02. 07.007	Teeth percussion	As needed
A03. 07.003	Diagnostics of the dento-facial system using methods and means of radiation imaging	As needed
A05. 07.001	Electrodontometry	As needed
A02. 07.008	Determination of the degree of tooth mobility.	According to the algorithm
A12. 07.002	Computer diagnostics of parodontal diseases using electronic probing devices	As needed
A06.07.003	Targeted intraoral contact radiography	As needed
A06.07.004	Orthopantomography	1
A06. 07.007	Intraoral radiography in occlusion	As needed
A06.07.010	Palpation of the maxillofacial region.	As needed
A06.31.006	Description and interpretation of radiographic images	As needed
A09. 07.002	Cytological examination of the cyst (abscess) contents of the oral cavity or the contents of a dental pocket	As needed
A09.07.005	Microscopic examination of the discharge from the mouth for sensitivity to	As needed

	antibacterial and antifungal agents	
B01.065.01	Attendance (examination, consultation) of a dentist therapist, primary	1
B01.066.01	Attendance (examination, consultation) of a dentist orthopedist, primary	1
B01.067.01	Attendance (examination, consultation) of a dental surgeon, primary	As needed
B01.063.001	Attendance (examination, consultation) of a dental orthodontist, primary	As needed
B01.054.001	Examination (consultation) of a physiotherapist	As needed

\* "1" – if once; "according to the algorithm" – if it is necessary to do several times (2 or more); "as needed" – if it is not necessary (at the discretion of the attending physician)

#### **7.8.4. Characteristics of algorithms and features of performing diagnostic measures**

Diagnostics is aimed at making the diagnosis that corresponds to the patient's model, excluding complications, determining the opportunity to start treatment without additional diagnostic and therapeutic and preventive measures.

For this purpose, all patients by all means undergo taking their history, an examination of the mouth and teeth, as well as other necessary examinations, the results of which are entered in the medical card of the dental patient (form 043/y).

#### **Taking the history**

When taking the history, complaints and the timing of their onset are found out. As a rule, the patient complains of pain from all types of irritants and / or spontaneous one; bleeding of the gums when brushing teeth, during meals or spontaneous; localized mobility of the teeth and their displacement, bad breath, defects in fillings and orthopedic structures, aesthetic discomfort. It is specified how many years the patient has been suffering from this disease or when the first symptoms appeared, whether he was treated earlier for this disease, the nature of the treatment, its volume (according to the patient) is found out, the result (sustained improvement, temporary improvement, without improvement or deterioration).

The presence of general somatic diseases in the patient, his allergic history are identified. The dentist finds out whether the patient performs proper hygienic care of the mouth.

Visual examination, external examination of the maxillofacial area, examination with additional tools.

When examining the maxillofacial region, the presence of visible changes is noted, the lymph nodes of the head and neck are palpated bimanually and bilaterally, comparing the right and left halves.

When examining the mouth, the condition of the dentition, the mucous membrane of the mouth and throat, its color, moisture content, the presence of pathological changes are evaluated. Special attention is paid to the depth of the vestibule, the nature of the lingual frenulum and the labial frenulum attachment, strands of the mucous membrane in the vestibule of the mouth. The dentist determines the state of occlusion, anomalies in the position of individual teeth, as well as the dentition as a whole, the presence of tremas, diastemas.

The dentist also determines the condition of the mucous membrane, its color, the degree of edema, the degree of moisture, the nature of saliva.

Assessment of periodontal tissues condition is carried out by probing using a periodontal probe (as well as electronic probing devices). At this, the presence of bleeding gums, the depth of the periodontal pocket, the magnitude of the gum recession, the presence of dental deposits and their nature, the presence of a discharge from the periodontal pocket are evaluated. Probing of the periodontal pocket is carried out at 6 points of each tooth (148eveling148-distal, vestibular, 148eveling148-medial, lingual-distal, lingual and lingual-medial). In multi-root teeth, the presence of furcation defects and their class are evaluated using a furcation probe. See Appendices №4, №10.

Tooth mobility is an important metric criterion for assessing the condition of parodontal tissues. When planning treatment, examination of dental mobility is a mandatory diagnostic measure. When assessing teeth mobility, the most common is Entin classification, as well as Miller classification and Flezar modification. See Appendix №3

Occlusal contacts are evaluated using articulation paper, wax plates and / or electronic devices.

Special attention is paid to identification of improperly manufactured fillings, the functional state of existing orthopedic structures (removable and non-removable), orthodontic devices, as well as the correct care of prostheses.

On the basis of clinical and additional methods of examination, an odontoparodontogram is filled in according to V. Yu. Kurlandsky. See Appendix №16.

When assessing the level of hygiene, attention is paid to the patient's hygiene skills in mouth care: when, how many times a day he brushes his teeth, the method of cleaning, which pastes and brushes he uses, how often he changes them. Dental plaque indicators and hygiene indices are used to control the quality of tooth brushing. In addition to hygiene indices, the bleeding index is calculated to determine the degree of gum inflammation. See Appendices №2, №6.

As additional methods of examination, methods of X-ray diagnostics, microbiological and cytological studies, etc. are used.

At the end of the examination, which is carried out jointly with dental surgeons, orthopedic dentists, orthodontists, a comprehensive treatment plan is drawn up.

### **7.8.5. Requirements for the outpatient treatment**

Code	Name	Frequency of execution
A14. 07. 003	Oral hygiene	According to the algorithm
A16.07.055	Professional oral and dental hygiene	According to the algorithm
A13.31.007	Training in oral hygiene.	According to the algorithm
A14. 07. 004	Controlled brushing of teeth	According to the algorithm
B01.003.004.001	Local anesthesia	As needed
A22.07.002	Ultrasound removal of supra-gingival and subgingival dental deposits	As needed
A16.07.022	Removal of supra-gingival and subgingival dental deposits	According to the algorithm
A22. 07. 001	Ultrasound treatment of periodontal	According to

	pockets	the algorithm
A16.07.043	Closed curettage for parodontal diseases	According to the algorithm
A16.07.001	Tooth extraction	As needed
A16.07.021	Temporary splinting in parodontal diseases	As needed
A16.07.029	Algorithm of selective grinding of hard dental tissues	According to the algorithm
A16.07.030	Gingivectomy.	As needed
A16.07.048	Frenuloplasty	As needed
A16.07.046	Plastic surgery of the upper lip frenulum	As needed
A16.07.047	Plastic surgery of the lower lip frenulum	As needed
A16.07.049	Vestibuloplasty	As needed
A16.07.044	Flap surgery	As needed
A16.07.005	Restoration of the dentition integrity with fixed bridge prosthesis	As needed
A16.07.039	Prosthetics with partial removable laminar dentures	As needed
A16.07.038	Restoration of the dentition integrity with removable bridge prosthesis	As needed
A16.07.040	Prosthetics with removable clasp prostheses	As needed
A17.07.002	Physiotherapy effect on the maxillofacial area	As needed
A16.07.057	Removal of a fixed orthopedic structure	As needed
A16.07.053	Re-fixation of fixed orthopedic structures on permanent cement	As needed
A16.07.041	Permanent splinting with solid-cast removable structures for parodontal diseases	As needed
A25.07.001	Prescription of drug therapy for diseases of the mouth and teeth	As needed
B01.065.02	Attendance (examination, consultation) of a dentist therapist, repeated	1
B01.066.02	Attendance (examination, consultation) of a dentist orthopedist,	1

	repeated	
B01.067.02	Attendance (examination, consultation) of a dental surgeon, repeated	As needed
B01.054.001	Examination (consultation) of a physiotherapist	As needed

\* “1” – if once; “according to the algorithm” – if it is necessary to do several times (2 or more); “as needed” – if it is not necessary (at the discretion of the attending physician)

### **7.8.6. Characteristics of algorithms and features of performing drug-free assistance**

Drug-free assistance is aimed at eliminating one of the main etiological factors of parodontal diseases – bacterial biofilm and factors that ensure its accumulation. When removing dental deposits, it is a prerequisite to create a clean, biocompatible, smooth root surface by removing destroyed and infected tissues. At this, antiseptics and local antibiotics are considered as additional means. See Appendix №12.

Drug-free assistance also includes surgical, orthopedic and orthodontic treatment. To treat localized periodontitis of heavy severity, as a rule, it is necessary to manufacture temporary and / or permanent removable and

fixed orthopedic structures, the choice of which depends on the state of the hard tissues of the teeth in the focus of inflammation, the presence of defects in the dentition and the data of the odontoparodontogram according to V. Yu. Kurlandsky and other additional examination methods. See appendices №7, №11, №14, №15.

### **7.8.7. Requirements for pharmaceutical outpatient medical care**

Name of the group	Frequency (duration of treatment)
Antimicrobials for local treatment of oral diseases	According to the algorithm
Preparations for local anesthesia	As needed
Antimicrobials for systemic use	As needed
Nonsteroidal anti-inflammatory drugs;	As needed
Antihistamines	As needed

### **7.8.8. Characteristics of algorithms and features of the use of pharmaceutical means**

Before performing manipulations, if medically required, anesthesia is performed (application, infiltration, conductor), before anesthesia, the injection site is treated with an application anesthetic, if necessary. Additionally, therapeutic toothpastes based on antiseptics and other anti-inflammatory agents are used.

The basis of medical treatment of parodontitis is antiseptics. They are used in the form of oral baths, applications and irrigation. Non-steroidal anti-inflammatory drugs are prescribed to relieve pain and edema.

Antihistamines are prescribed after surgical interventions.

Antimicrobials of systemic action are prescribed for intoxication and complications after surgery.

### **7.8.9. Requirements for the regime of work, rest, treatment and rehabilitation**

After the treatment, dynamic monitoring is necessary – 4 times during the first year.

A control X-ray examination should be performed twice a year.

### **7.8.10. Requirements for patient care and auxiliary procedures**

There are no special requirements.

### **7.8.11. Requirements for dietary prescriptions and restrictions**

After performing surgical manipulations, it is not recommended to take food for two hours. On the day of surgery, it is recommended to avoid eating rough, hot food and not to chew on the operated side.

### **7.8.12. The form of the patient's informed voluntary consent when performing the protocol**

See Appendix № 8.

### **7.8.13. Additional information for the patient and his family members**

See Appendix № 9.

**7.8.14. Rules for changing the requirements when implementing Clinical recommendations (treatment protocols) “Parodontitis” and termination of the requirements of Clinical recommendations (treatment protocols)**

When identifying signs in the process of diagnosis that require carrying out

preparatory steps, the patient is transferred to the Clinical recommendations (treatment protocols) corresponding to the identified diseases and complications.

If signs of another disease requiring diagnostic and therapeutic measures are detected, along with signs of parodontitis, medical care is provided to the patient in accordance with the requirements of:

a) the section of these Clinical recommendations (treatment protocols) corresponding to parodontitis;

b) Clinical recommendations (treatment protocols) with the identified disease or syndrome.

**7.8.15. Possible outcomes and their characteristics**

Name of the outcome	Frequency of development, %	Criteria and Signs	Estimated time to reach the outcome	Continuity and phasing of medical care
Function compensation	40	No inflammation. Reduction of pathological mobility of teeth to 1-2 degree	After treatment	Dynamic observation 4 times a year.
Stabilization	50	Lack of both positive and negative dynamics	After treatment	Dynamic observation 4 times a year.
Development of iatrogenic complications	5	The onset of new lesions or leveling of the surface caused by the therapy (for example,	At any stage	Provision of medical care according to the protocol of

		allergic reactions)		appropriate care
Development of a new disease associated with the underlying medical condition	5	Relapse of periodontitis, its progression	In the absence of supportive parodontal treatment	Provision of medical care according to the protocol of appropriate care

#### **7.8.16. Cost characteristics of Clinical recommendations (treatment protocols) “Parodontitis”**

The cost characteristics are determined according to the requirements of regulatory documents.

#### **VIII. GRAPHICAL, SCHEMATIC AND TABULAR REPRESENTATION OF CLINICAL RECOMMENDATIONS (TREATMENT PROTOCOLS) “PARODONTITIS”**

Is not required

#### **IX. –MONITORING (if necessary)**

CRITERIA AND METHODOLOGY FOR MONITORING AND EVALUATING THE EFFECTIVENESS OF CLINICAL RECOMMENDATIONS IMPLEMENTATION (TREATMENT PROTOCOLS) “PARODONTITIS”

Monitoring is carried out throughout the entire territory of the Russian Federation.

The list of medical organizations where this document is monitored is determined annually by the organization responsible for monitoring.

The medical organization is informed about its inclusion in the list of monitoring Clinical recommendations (treatment protocols) in writing.

Monitoring includes:

- ✓ collecting information: about the management of patients with dental caries in dental medical organizations;
- ✓ analysis of the data received;
- ✓ making a report on the results of the analysis;

- ✓ submission of the report to a group of developers of these Clinical recommendations (treatment protocols).

The initial data for monitoring are:

- ✓ medical documentation – medical card of a dental patient (form 043/y);
- ✓ tariffs for medical services;
- ✓ tariffs for dental materials and medicines.

If necessary, other documents may be used when monitoring Clinical recommendations (treatment protocols).

In dental medical organizations defined by the monitoring list, a patient's card is drawn up every six months on the basis of medical documentation (see Appendix №12) on the treatment of patients with dental pulp disease that correspond to the patient's models in these Clinical recommendations (treatment protocols).

The indicators analyzed in the monitoring process include: criteria for inclusion and exclusion from Clinical recommendations (treatment protocols), lists of mandatory and additional medical services, lists of mandatory and additional medicines, disease outcomes, the cost of performing medical care according to Clinical recommendations (treatment protocols), etc.

## PRINCIPLES OF RANDOMIZATION

These Clinical Recommendations (treatment protocols) do not provide for randomization (of medical institutions, patients, etc.).

## THE PROCEDURE FOR EVALUATING AND DOCUMENTING SIDE EFFECTS AND COMPLICATIONS DEVELOPMENT

Information about side effects and complications that developed during the diagnosis and treatment of patients is recorded in the patient's card.

## PROCEDURE FOR EXCLUDING A PATIENT FROM MONITORING

The patient is considered included in the monitoring when the Patient's Card is filled in for him. Exclusion from monitoring is carried out if it is impossible to continue filling out the Card (for example, failure

to attend the medical appointment) (see appendix № 12). In this case, the Card is sent to the organization responsible for monitoring, with a note about the reason for excluding the patient from the Clinical recommendations (treatment protocols).

#### INTERIM EVALUATION AND MODIFICATION OF CLINICAL RECOMMENDATIONS

The assessment of implementing Clinical recommendations (treatment protocols) is carried out once a year based on the results of the analyzing the information obtained during monitoring. Changes to Clinical recommendations (treatment protocols) are made if information is received:

- a) about the presence in the Clinical recommendations (treatment protocols) of requirements that cause damage to the health of patients,
- b) upon receipt of convincing data on the need to change the requirements of Clinical recommendations (treatment protocols) of the mandatory level. The decision on changes is made by the development team.

#### PARAMETERS FOR ASSESSING THE QUALITY OF LIFE WHEN IMPLEMENTING CLINICAL RECOMMENDATIONS

To assess the life quality of a patient with a dental pulp disease that corresponds to the models of Clinical recommendations (treatment protocols), an analog scale is used (see Appendix № 10).

#### ASSESSMENT OF THE COST OF IMPLEMENTING CLINICAL RECOMMENDATIONS AND THE QUALITY PRICE

Clinical and economic analysis is carried out in accordance with the requirements of regulatory documents.

#### COMPARISON OF RESULTS

When monitoring Clinical recommendations (treatment protocols), the results of meeting its requirements, statistical data, and performance indicators of medical organizations are compared annually.

#### THE PROCEDURE FOR GENERATING THE REPORT

The annual report on the results of monitoring includes quantitative results obtained during the development of medical records, and their qualitative analysis, conclusions, suggestions for updating Clinical recommendations (treatment protocols). The report is submitted to the group of developers of these clinical recommendations.

The results of the report can be published in the open press.

THE LIST OF DENTAL MATERIALS, TOOLS AND EQUIPMENT  
NECESSARY FOR THE WORK OF A DENTIST

**Mandatory assortment**

- ✓ Dental installation
- ✓ Universal dental tray
- ✓ Dental glasses for mixing
- ✓ Dental mirror
- ✓ Dental tweezers
- ✓ Probe for furcations
- ✓ Periodontal probe
- ✓ Universal curettes
- ✓ Scalpel Pen
- ✓ Scalpel blade
- ✓ Dental elevator
- ✓ Micro-dental elevator
- ✓ Surgical curettes
- ✓ Scissors
- ✓ Micro scissors
- ✓ Needle holder
- ✓ Pean's forceps
- ✓ Periodontal knife
- ✓ Tweezers
- ✓ Suture material
- ✓ Articulation paper
- ✓ Air-turbine handpiece
- ✓ Straight handpiece
- ✓ Angular handpiece
- ✓ Burs for an air-turbine handpiece
- ✓ Burs for a straight handpiece
- ✓ Burs for an angular handpiece
- ✓ Rubber polishing heads
- ✓ Polishing brushes
- ✓ Metal strips of various degrees of granularity
- ✓ Plastic strips
- ✓ Disposable gloves

- ✓ Disposable mask
- ✓ Disposable saliva ejector
- ✓ Disposable glass
- ✓ Safety glasses
- ✓ Disposable syringes
- ✓ Cartridge syringe
- ✓ Needles for a cartridge syringe
- ✓ Materials for bandages and temporary fillings.
- ✓ Antiseptics for medical treatment of the oral cavity or periodontal pockets
- ✓ Abrasive paste that does not contain fluoride for cleaning the tooth surface
- ✓ Paste for polishing fillings and teeth
- ✓ Means for teaching the patient individual oral hygiene (toothbrushes, pastes, dental floss, interdental brushes)
- ✓ Means for staining teeth during hygiene measures
- ✓ Apron for the patient
- ✓ Baseplate wax

**Additional assortment:**

- ✓ Disc holder for an angular handpiece for polishing discs
- ✓ Retraction threads
- ✓ Carborundum heads for a straight handpiece
- ✓ Diamond heads for a straight handpiece
- ✓ Diamond discs
- ✓ Two-sided explorer probe
- ✓ Paper blocks for mixing
- ✓ Crescent-shaped scaler (with a straight blade; with a curved blade)
- ✓ Zone-specific curettes
- ✓ Gracie after five curettes
- ✓ Gracie mini five curettes
- ✓ Gracie mini-micro curettes
- ✓ Furcation curettes
- ✓ Implacker
- ✓ The sound device
- ✓ Ultrasonic device of magnetostrictive type

- ✓ Ultrasonic device of piezoelectric type
- ✓ Handpieces of various shapes and sizes for sound and ultrasonic devices
- ✓ Powder-blasting machines (air-abrasive systems)
- ✓ Powder for powder blasting machines
- ✓ Rongears (bone clippers)
- ✓ Surgical chisel
- ✓ Mini chisel
- ✓ Periodontal files
- ✓ Atraumatic tweezers
- ✓ Micro-tweezers
- ✓ Forceps for marking the periodontal pocket
- ✓ Retractor
- ✓ Ultrasound equipment for parodontal surgery
- ✓ A set of ultrasonic handpieces for parodontal surgery
- ✓ Gum edge trimmer
- ✓ Protective screen
- ✓ Glasses for working with a helio-lamp
- ✓ Color scale
- ✓ Glass ionomer cement
- ✓ Composite materials of chemical curing
- ✓ Light-cured composite materials
- ✓ Adhesive systems for light-curing composites
- ✓ Adhesive systems for light-curing composites
- ✓ Etching gel based on 35-38% orthophosphoric acid
- ✓ Composite photopolymerization lamp
- ✓ Device for electrodontodiagnostics
- ✓ Caries diagnostic device
- ✓ Interdental wooden wedges
- ✓ Interdental wedges transparent
- ✓ Matrix holder
- ✓ Matrix fixing system
- ✓ Tools for creating contact points on molars and premolars
- ✓ Applicator gun for capsule composite materials
- ✓ Applicators
- ✓ Anchor pins
- ✓ Reamers to anchor pins

- ✓ Micromotor
- ✓ Carborundum discs
- ✓ Standard impression spoons
- ✓ Alginate impression mass
- ✓ Double-layer silicone impression mass
- ✓ Modeling wax (lavax)
- ✓ Clamp wire
- ✓ Polishers for a straight handpiece
- ✓ Color scale for determining the color of the facing and artificial teeth
- ✓ Plaster of Paris
- ✓ Die stone
- ✓ A spatula for mixing alginate impression materials and gypsum
- ✓ Rubber cup
- ✓ Zinc phosphate cement for permanent fixation of fixed structures
- ✓ Gas burner
- ✓ Cement for temporary fixation of fixed structures
- ✓ Nippers
- ✓ Crown scissors
- ✓ Crown forceps
- ✓ Anvil
- ✓ A dental hammer
- ✓ Crown pin cylinder
- ✓ 2% solution of methylene blue
- ✓ Standard cotton rolls
- ✓ Box for standard cotton rolls
- ✓ Tips for isolating the ducts of the parotid salivary glands
- ✓ Elevators different in shape and size
- ✓ Forceps different in shape and size for the upper and lower jaws
- ✓ Curettage spoon
- ✓ Adhesive plaster

## Algorithms for determining indices

### Algorithm for determining the plaque index by Silness-Loe

The index estimates the amount of soft plaque in the gingival area. The assessment is carried out visually and with a probe without staining, 4 surfaces are examined, for a better diagnosis, the area of the tooth neck is pre-dried with an air jet.

The intensity of the plaque, the evaluation criteria:

- 0 – there is no plaque on the tip of the probe;
- 1 – a small amount of plaque;
- 2-a thin layer of plaque near the neck, there is a significant amount at the tip of the probe;
- 3-a significant amount of plaque in the gingival region and in the interdental spaces.

The index is calculated using the formula:

Total index = (sum of points) / (number of teeth examined).

### Muellemann bleeding index (modified by Cowell).

It determines the degree of bleeding in the gingival sulcus when probing or when pressure is applied to the gingival papilla.

In the area of “Ramfjord’s teeth” (16, 21, 24, 36, 41, 44) from the buccal and lingual (palatine) surfaces, the tip of the periodontal probe, without pressure, is passed from the medial to the distal surface of the tooth.

Evaluation criteria:

- 0 – there is no bleeding after the examination;
- 1-bleeding appears no earlier than after 30 seconds;
- 2-bleeding occurs either immediately after the examination, or within 30 seconds;
- 3-bleeding is noted when eating or brushing teeth.

The index value = (the sum of the indicators of all teeth) / (the number of teeth).

### **Algorithm for determining teeth mobility**

The basis of the generally accepted classification of pathological mobility of teeth according to D. A. Entin (Entin D. A. 1954) is the direction of the visually determined displacement of the tooth relative to its axis.

#### **Determination of teeth mobility by D. A. Entin.**

Grade I-displacement of the tooth only in the vestibular-oral direction;

Grade II-visible displacement of the tooth both in the vestibular-oral and medio-distal directions;

Degree III-displacement of the tooth in the vestibular-oral, medio-distal and vertical directions: when pressing, the tooth sinks into the socket, and then it returns to its original position again.

#### **Assessment of teeth mobility by Miller scale in Flezar modification.**

0-stable tooth, there is only physiological mobility;

1 – displacement of the tooth relative to the vertical axis is slightly larger, but does not exceed 1 mm;

2-the tooth is displaced by 1-2 mm in the buccal-lingual direction, the function is not impaired;

3-mobility is sharply expressed, while the tooth moves not only in the buccal-lingual direction, but also vertically, its function is impaired.

**An algorithm for determining the class of a furcation defect.**

Furcation defect of the alveolar bone is a defect in the bone tissue of the inter-root septum in the furcation area of multi-root teeth. To determine the state of a furcation defect, a furcation probe is used. Furcation is probed in the horizontal direction. Based on the magnitude of the horizontal propagation of the process, a class of furcation lesion is determined. There are several classifications of furcation defects.

**Classification I. Glickman (1958):**

Class I-resorption of the alveolar bone, which exposes the furcation area of the roots, but is not accompanied by the destruction of the inter-root bone.

Class II-the midradicular bone is partially lost, but there is no penetration defect.

Class III-a penetration defect in the furcation area is detected during probing, but is hidden by the gum.

Class IV-a penetration defect of the midradicular septum, the furcation area can be examined in the oral cavity and it is not hidden by the gum.

**Classification of P. J. Heins, S.P. Canter (1968):**

Class I-the top of the alveolar ridge exposes the arch of the roots furcation, horizontal probing of the bone defect can be accompanied by immersion of a graduated probe up to 2 mm in the direction of the midradicular septum.

Class II-in addition to the signs of a furcation defect of class I, it is possible to horizontally immerse the graduated probe in the direction of the midradicular septum by more than 2 mm, but the tool does not penetrate to the opposite side.

Class III-corresponds to the free penetration of a graduated probe on the opposite side when it moves in the horizontal direction.

**Classification of J. Lindhe (1983):**

The initial (1 class) destruction of the midradicular septum by 1/3 of its cross-section or less.

Partial (class 2) destruction of the midradicular septum exceeds 1/3 of its cross-section, but does not form a penetration defect.

Total (class 3) destruction of the midradicular bone in the horizontal direction with the formation of a penetration defect.

## **Controlled brushing of teeth**

In order to develop the patient's skills of oral care (brushing teeth) and the most effective removal of soft plaque from the teeth surfaces, the patient is taught oral hygiene techniques. The technique of brushing teeth is demonstrated on models. Oral hygiene products are chosen individually. Training in oral hygiene skills helps to prevent the development of inflammatory periodontal diseases (the level of evidence strength evidence C).

Controlled brushing of teeth – brushing of teeth, which the patient performs independently in the presence of a specialist (dentist, dental hygienist) in the dental office or oral hygiene room, if the necessary hygiene products and visual aids are available. The purpose of this event is to correct the shortcomings of the dental cleaning technique. Controlled brushing of teeth makes it possible to achieve effective maintenance of oral hygiene level (the level of evidence strength evidence C).

Professional oral hygiene includes removal of soft and hard dental deposits from the surface of the tooth and makes it possible to prevent the development of inflammatory periodontal diseases (the level of evidence strength evidence A).

### **The algorithm of teaching oral hygiene**

#### **First visit**

A dentist or dental hygienist determines the hygiene index, then demonstrates to the patient the technique of brushing teeth with a toothbrush, interdental brushes and dental floss, using models of dentition, or other demonstration means.

There are different methods of brushing teeth based on circular, vibrating, horizontal and vertical movements. It is not the technique itself that is important, but the effectiveness of cleansing, the sequence of the procedure and the absence of harmful effects.

Teeth cleaning begins with a section in the area of the upper right masticatory teeth, sequentially moving from one segment to another. In the same order, teeth are cleaned on the lower jaw.

Attention should be paid to the fact that the working part of the toothbrush should be positioned at an angle of 45° to the tooth, make cleaning movements from the gum to the tooth, while simultaneously removing plaque from the teeth and gums. The chewing surfaces of the teeth should be cleaned with horizontal (reciprocating) movements so that the brush fibers penetrate deep into the fissures and interdental spaces. The vestibular surface of the frontal group of teeth of the upper and lower jaws should be cleaned with the same movements as molars and premolars. When cleaning the oral surface, the brush handle should be placed perpendicular to the occlusal plane of the teeth, while the fibers should be at an acute angle to the teeth and capture not only the teeth, but the gum as well.

Cleaning is finished by circular movements of the toothbrush with closed jaws, massaging the gums. The cleaning time is 3 minutes.

For high-quality cleaning of the contact teeth surfaces, it is necessary to use interdental brushes and dental floss.

Individual choosing of oral hygiene products is carried out taking into account the dental status of the patient (the condition of the hard dental tissues and periodontal tissues, the presence of dental anomalies, removable and non-removable orthodontic and orthopedic structures) (Appendix 6).

### **Next visit**

In order to consolidate the acquired skills, individual oral hygiene is monitored (controlled brushing of teeth).

### **Algorithm of controlled brushing of teeth**

Controlled dental cleaning is a dental cleaning that the patient performs independently in the presence of a dentist.

### **First visit**

- Treatment of the patient's teeth with a staining agent, determination of the hygienic index, demonstration to the patient of the places of the greatest accumulation of plaque with the help of a mirror.
- Brushing the teeth in the usual way for the patient.
- Re-determination of the hygiene index, evaluation of the effectiveness of brushing teeth (comparison of the hygiene index values

before and after brushing teeth), demonstration to the patient of colored areas where plaque was not removed during brushing with the help of a mirror.

- Demonstration of the correct technique of brushing teeth on models, recommendations to the patient on correcting the shortcomings of hygienic mouth care, the use of dental floss and additional hygiene products (special toothbrushes, toothbrushes, end-tufted brushes, irrigators — if medically required).

### **Next visit**

Determination of the hygiene index, in an unsatisfactory level of oral hygiene

- the procedure is repeated. The patient is informed about the need to come for a preventive examination to a doctor once every 6 months.

### **Professional oral and dental hygiene**

#### **Stages of professional hygiene:**

- teaching the patient individual oral hygiene;
- controlled brushing of teeth
- removal of supra-and subgingival dental deposits;
- polishing of tooth surfaces;
- elimination of factors contributing to the accumulation of plaque;
- applications of remineralizing and fluorinated agents (with the exception of areas with high content of fluoride in drinking water, more than 1 mg/l);
- motivation of the patient to the prevention and treatment of dental diseases.

#### **The procedure is carried out in one visit.**

When removing dental deposits (tartar, soft plaque), a number of conditions should be observed:

- treat the mouth with an antiseptic solution (0.06% chlorhexidine solution, 0.05% potassium permanganate solution);
- in pronounced hyperesthesia of the teeth and the absence of general contraindications, removal of
- dental deposits should be carried out under local

anesthesia;

- isolate the treated teeth from saliva;
- attention should be paid to the fact that the hand holding the instrument should be fixed on the patient's chin or adjacent teeth, the terminal rod of the instrument is located parallel to the axis of the tooth, the main movements are lever-like and scraping – should be smooth, non-traumatic.

In the field of metal-ceramic, ceramic, composite restorations, implants (plastic tools are used in the processing of the latter), a manual method of removing dental deposits is used.

Ultrasound devices should not be used in patients with respiratory and infectious diseases, as well as in patients with pacemakers.

To remove plaque and polish the surfaces of teeth, rubber caps are used, for chewing surfaces — rotating brushes, for contact surfaces — rotating interdental brushes, rubber cones, super flosses, flosses and abrasive strips. Polishing paste should be used, starting with coarse and ending with fine one. When processing the surfaces of implants, fine polishing pastes and rubber caps should be used.

It is necessary to eliminate the factors that contribute to plaque accumulation: remove the overhanging edges of the fillings, re-polish the fillings.

The frequency of professional oral and dental hygiene depends on the patient's dental status (the hygienic state of the oral cavity, the intensity of dental caries, the condition of periodontal tissues, the presence of a non-removable orthodontic structure and dental implants). The minimum frequency of professional hygiene is twice a year.

**GENERAL RECOMMENDATIONS FOR CHOOSING HYGIENE PRODUCTS DEPENDING ON THE PATIENT'S DENTAL STATUS**

Patient population	Recommended hygiene products
The population of areas with a fluoride content in drinking water of less than 1 mg/l. The presence of foci of enamel demineralization, hypoplasia in the patient	A soft or medium-hard toothbrush, anti-cariious toothpastes — fluoride and calcium – containing (according to age), dental flosses, fluoride-containing rinses
The population of areas with a fluoride content in drinking water of more than 1 mg/l. The presence of fluorosis manifestations in the patient	A soft or medium-hard toothbrush, toothpastes that do not contain fluoride, calcium-containing; dental flosses that are not impregnated with fluorides, rinses that do not contain fluoride
Patients with inflammatory parodontal diseases (in the period of exacerbation)	Toothbrush with soft bristles, anti-inflammatory toothpastes (with medicinal herbs, antiseptics*, salt additives), dental flosses, rinses with anti-inflammatory components  * Note: the recommended course of using toothpastes and rinses with antiseptics is 7-10 days
The presence of dental anomalies in the patient (crowding, dystopia of teeth)	A medium-hard toothbrush and therapeutic and prophylactic toothpaste (according to age), dental flosses, dental brushes, rinses
The presence of braces in the patient's mouth	Orthodontic toothbrush of medium hardness, anti-cariious and anti-inflammatory toothpastes (alternation), toothbrushes, end-tufted brushes, dental floss (floss), rinses with anti-cariious and anti-inflammatory components, irrigators
The presence of dental implants in the patient	A toothbrush with different heights of bristle bundles*, anti-cariious and anti-inflammatory toothpastes (alternation), toothbrushes, end-tufted brushes, dental flosses, alcohol-free rinses with anti-

	<p>carious and anti-inflammatory components, irrigators. Toothpicks and chewing gum should not be used</p> <p>* Note: toothbrushes with even trimming of the bristles are not recommended to use due to their lower cleaning efficiency</p>
The presence of removable orthopedic and orthodontic structures in the patient	Toothbrush for removable dentures (double-sided, with hard bristles), tablets for cleaning removable dentures
Patients with hypersensitivity of the teeth.	Soft-bristled toothbrush, toothpastes for reducing tooth sensitivity (containing strontium chloride, potassium nitrate, potassium chloride, hydroxyapatite), dental flosses, rinses for sensitive teeth
Patients with xerostomia	A toothbrush with very soft bristles, a toothpaste with enzyme systems and low pricing, an alcohol-free rinse aid, a moisturizing gel, dental flosses

**Algorithms for filling carious cavities and performing orthopedic manipulations (see PVB Diseases of periapical tissues)**

***Algorithm and features of permanent splinting with solid-cast removable structures for parodontal diseases.***

The main tasks of orthopedic treatment are to stabilize the clinical situation and transfer the subcompensated and decompensated state to the compensated and subcompensated, respectively. These tasks are achieved by the use of permanent prosthetics and splinting with the use of removable, non-removable structures and their combination. Planning of orthopedic treatment is carried out taking into account the odontoparodontogram, types of stabilization proposed by V. Y. Kurlyandsky. Splinting is carried out with one-piece-cast removable prostheses and/or

with clasp prostheses. When making clasp prostheses, especially splinting ones, parallelometry is mandatory; after performing it and obtaining the panoramic the issue of planning the design of the clasp prosthesis is analyzed .

The main principles of this planning are consistency in the choosing individual elements of the prosthesis and ways of distributing the functional load depending on the morphological conditions and the functional state of the supporting tissues.

Planning of supporting and retaining elements begins with choosing clasps, the design of which conforms the most the data of anatomical and functional conditions.

When planning and manufacturing solid-cast removable structures, an important task is to prepare the dentition:

- a) preparing the place for clasps and occlusal inlays;
- b) restoring the anatomical shape of the retainer teeth;
- c) immobilizing (splinting) for an even distribution of the masticatory load.

**ALGORITHM AND FEATURES OF THE MANUFACTURING CLASP PROSTHESES**

### **First visit**

Before starting treatment, it is necessary to make diagnostic models that give the opportunity to determine the presence of space for the occlusive parts of the clamps. After that, a decision is made about prosthetics, and treatment is started at the same visit. In the absence of a place on the model, the areas to be ground are marked, after which necessary grinding of the hard dental tissues of the oral cavity is carried out in the places where the occlusal onlays will be located, artificial deepening of the natural teeth fissures is permissible. If necessary, the retainer teeth are covered with artificial clasp crowns.

The first stage of manufacturing a clasp prosthesis is taking impressions. A working cast (impression) is taken from the jaw on which a prosthetic appliance will be made, from the opposite one — the occlusal one, using standard mouth spoons and alginate impression pastes. It is recommended to cant the edges of mouth spoons with a narrow strip of adhesive plaster before taking the impressions for better retention of the impression material. After removing the spoons from the oral cavity, the quality of the casts (impressions) is checked (displaying the anatomical relief, the absence of cavities, etc.).

Models are cast: the working model is made of die stone, the bite model is made of simple plaster.

Parallelometry is performed and the route of introducing and removing the splinting clasp prosthesis is determined.

### **Next visit**

Application and fitting a solid cast frame of a clasp prosthesis. Special attention should be paid to the lack of pressure of the clasp prosthesis arch on the mucous membrane, the accuracy of its fit and coverage with supporting and retaining elements (clasps and occlusal onlays) of the retainer teeth, lack of balancing.

The arch of the clasp prosthesis on the lower jaw throughout its entire length should be spaced away from the mucous membrane at the upper edge by 0.5—0.6 mm, at the lower — by at least 1 mm. The arch of the prosthesis on the upper jaw is spaced away from the mucosa by 0.6-1 mm. Deviation from these requirements may lead to decubitus formation in the future. Making corrections to the metal frame is undesirable, because its thinning is fraught with a fracture or a decrease in rigidity.

Determination of the centric ratio of the jaws is carried out using wax bases made in the dental laboratory with occlusal rims. Special attention should be paid to the formation of a correct prosthetic plane, determining the height of the lower facial part.

The choice of color, size and shape of artificial teeth is made in accordance with the remaining teeth and individual characteristics (patient's age, size and shape of the face).

### **Next visit**

Examination of the prosthesis design (placement of teeth on a wax structure carried out in a dental laboratory) on a wax basis to assess the correctness of all previous clinical and laboratory stages of manufacturing the prosthesis and making necessary corrections.

### **Next visit**

Introducing and fitting the finished clasp prosthesis after the laboratory stage of replacing the wax base of the saddle part with a plastic one.

Before introducing , it is necessary to assess the quality of the prosthesis base (absence of cavities, sharp edges, protrusions, roughness, etc.). The color may indicate poor-quality polymerization.

The prosthesis is introduced into the oral cavity, the density of the teeth coming together and the fixation of the clasp prosthesis are checked, the accuracy of its fit and coverage with supporting and retaining elements (clasps and occlusal onlays) of the retainer teeth, the absence of balancing.

### **Next visit**

The first correction is prescribed on the next day after the delivery of the prosthesis, then according to the indications (no more than once every three days). The adaptation period can last up to 1.5 months.

If there is pain in the area of the prosthetic bed tissues associated with an injury to the mucous membrane, the patient is recommended to immediately stop using the prosthesis, visit the dentist, resuming the use of the prosthesis 3 hours before the visit to the dentist.

In case of mechanical damage to the mucous membrane, ulcers formation under the saddle part of the clasp prosthesis, the areas of the prosthesis in these places are minimally ground off.

Correction of the prosthetic basis is carried out until the first subjective sensation of pain reduction appears. In case of incorrect manufacturing the clasp prosthesis arch, its minimal grinding is allowed. However, it should be borne in mind that the thinning of the arch is fraught with a fracture or a decrease in rigidity.

Drug therapy with anti-inflammatory drugs and remedies that accelerate the oral mucosa epithelization is prescribed.

### **Patients with allergic reactions**

If there is an allergy in the history, cutaneous tests are performed on the material of the prosthesis basis. In case of a positive reaction to plastic, it is recommended to make clasp prostheses using colorless plastic. If the patient has an allergic reaction to the metal from which the frame is made, the metal parts are gold-coated galvanically.

The patient is instructed about the rules for using the structure and the need for regular visits to the dentist once every six months is indicated.

FORM OF VOLUNTARY INFORMED CONSENT OF THE  
PATIENT WHEN PERFORMING THE PROTOCOL APPENDIX TO  
THE MEDICAL RECORD № \_\_\_\_\_

Patient

\_\_\_\_\_

Full name

\_\_\_\_\_

receiving explanations about the diagnosis of parodontitis, I received information:

about the features of the disease course

\_\_\_\_\_

probable duration of treatment \_\_\_\_\_

about a probable forecast \_\_\_\_\_

The patient is offered a plan of examination and treatment, including

\_\_\_\_\_

The patient is offered \_\_\_\_\_

from materials

The approximate cost of treatment is about

\_\_\_\_\_

The patient knows the price list accepted in the clinic.

Thus, the patient received explanations about the purpose of treatment and information about the planned methods of diagnosis and treatment.

The patient is informed about the need to prepare for treatment:

The patient is informed about the need for treatment and received instructions and recommendations for care.

The patient is informed that non-compliance with the doctor's recommendations may adversely affect the state of health.

The patient received information about typical complications associated with this disease, with necessary diagnostic procedures and with treatment.

The patient is informed about the probable course of the disease and its complications in case of refused treatment.

The patient had the opportunity to ask any questions of interest regarding his state of health, disease and treatment and received satisfactory answers to them.

The patient received information about alternative methods of treatment, as well as their approximate cost.

The conversation was conducted by a doctor \_\_\_\_\_ (doctor's signature).

“ \_\_\_\_\_ ” \_\_\_\_\_ 200\_\_\_\_.

The patient agreed with the proposed treatment plan, which he signed with his own hand \_\_\_\_\_

(patient's signature)

or signed by his legal representative \_\_\_\_\_

(signature of the legal representative)

or

which is certified by those who were present during the conversation

\_\_\_\_\_  
(doctor's signature)

(signature of the witness)

The patient did not agree with the treatment plan (refused the proposed type of prosthesis), which he signed with his own hand.

(patient's signature)

or signed by his legal representative \_\_\_\_\_  
(signature of the legal representative)

or

which is certified by those who were present during the conversation

\_\_\_\_\_  
(doctor's signature)

(signature of the witness)

The patient expressed a desire:

- in addition to the proposed treatment, undergo an examination
- get an additional medical service
- instead of the proposed filling material, get

The patient received information about the specified method of examination/treatment.

Since this method of examination/treatment is also shown to the patient, it is included in the treatment plan.

“ \_\_\_ ” \_\_\_\_\_ 20 \_\_\_\_\_

(patient's signature)

(doctor's signature)

Since this method of examination/treatment is not shown to the patient, it is not included in the treatment

plan.

“ ” \_\_\_\_\_ 20 \_\_\_\_\_

(patient's signature)

(doctor's signature)

## ADDITIONAL INFORMATION FOR THE PATIENT

1. Teeth should be cleaned with a soft toothbrush with paste twice a day. After eating, you should rinse your mouth to remove food residues.

2. To clean the interdental spaces, you can use interdental brushes, dental floss.

3. By the recommendation (administration) of the attending dentist, use an irrigator, after learning the rules of its use.

4. Bleeding during toothbrushing should not stop hygiene procedures. If the bleeding does not resolve within 3 days, it is necessary to consult a doctor.

5. Professional hygiene (removal of supra- and subgingival dental deposits) should be carried out at least once every 4 months by the attending dentist.

6. If, after professional hygiene, there is an increased sensitivity of the hard dental tissues, use special toothpastes to reduce the teeth sensitivity and consult your dentist.

7. After splinting, it is not recommended to bite off hard food to avoid damage to the splint.

8. After performing operations on soft tissues (frenulotomy, frenulectomy, vestibuloplasty) and after tooth-preserving operations, it is necessary:

- strictly follow the instructions and recommendations of the attending dentist;
- make oral baths with antiseptic solutions;
- if there is pain after a surgical intervention, it is necessary to take an analgesic drug;

- in case of edema that occurs 2-3 days after a surgical intervention, take any antihistamine and immediately consult your dentist;

9. Within 3 days after the surgical intervention, avoid physical loads and staying in places with high temperature (baths, saunas, hot showers).

10. Be sure to attend scheduled examinations.

### Algorithm for determining the depth of a periodontal pocket

Determining the depth of a periodontal pocket is one of the important components of parodontal examination. For this purpose, a calibrated periodontal probe is used. The depth of the periodontal pocket is measured from the gingival margin to the bottom of the pocket. The tool is placed parallel to the long axis of the tooth, tightly pressing it to the surface of the tooth. On each side – vestibular and oral – the indicators obtained at three points are recorded: distally, along the midline and medially in the parodontogram.

In addition, the parodontogram records the indicators of gum recession with a continuous line. Recession is measured from the enamel-cement border to the gingival margin with a calibrated periodontal probe.

The sum of indicators of periodontal pocket depth and gum recession means loss of attachment.

		Верхняя челюсть															
Глубина ПК																	
Глубина ПК																	
Глубина ПК																	
		18	17	16	15	14	13	12	11	21	22	23	24	25	26	27	28
	В																
	О																
Глубина ПК																	
Глубина ПК																	
Глубина ПК																	
		Нижняя челюсть															
Глубина ПК																	
Глубина ПК																	
Глубина ПК																	
		48	47	46	45	44	43	42	41	31	32	33	34	35	36	37	38
	О																
	В																
Глубина ПК																	
Глубина ПК																	
Глубина ПК																	

### **Tooth extraction algorithm**

Surgical intervention is performed at least a week after professional hygiene. The operation is performed under local anesthesia. The circular ligament is separated from the tooth neck and the gum from the edge of the alveoli, after which the tooth is extracted. Curettage of the tooth socket and hemostasis of the postoperative wound are performed.

### **Algorithm for opening a parodontal abscess**

Treatment of parodontal abscess of gingival origin consists in the possibility of its draining through the gingival margin. In the apical location of the parodontal abscess, an incision is made along the lower border of the inflammatory focus.

The operation is performed under local anesthesia. In the apical location of the parodontal abscess, an incision is made along the lower border of the inflammatory focus to create an outflow, then antiseptic treatment is carried out and, if necessary, drained.

### **Algorithm of gingivectomy**

Gingivectomy is excision of a part of the gum.

Surgical intervention is performed at least a week after professional hygiene. The operation is performed under local anesthesia. Using Crane-Kaplan tweezers, the bottom of the gingival pocket is marked, then a part of the gum is cut off with a scalpel located at an obtuse angle to the tooth crown. Special attention is paid to the scalpel to be in constant contact with the surface

of the tooth; The surface is cleaned of dental deposits, the root surface is polished, the surgical wound is washed with an antiseptic solution; after that, an insulating parodontal dressing is applied.

### **The algorithm of frenuloplasty on the upper (lower) lip, the tongue.**

Frenulotomy is a dissection of the frenulum from the top of the attachment to the base.

Frenulectomy is a complete excision of the frenulum, including its attachment to the alveolar process

Surgical intervention is performed at least a week after professional hygiene. The operation is performed under local anesthesia. The frenulum is caught at the base and excision is carried out with scissors. Stitches are applied along the edges of the diamond-shaped incision. Special attention is paid to tissue opposition.

### **Algorithm of vestibuloplasty**

Vestibuloplasty is an operation to deepen the vestibule of the oral cavity

Surgical intervention is performed at least a week after professional hygiene. The operation is performed under local anesthesia. Using a scalpel an incision is made on the mucous membrane of the lip at the place of its attachment to the gum and, parallel to the periosteum, a 10-15 mm deepening of the vestibule is carried out by blunt dissection, an iodoform swab is applied over the entire surface of the wound. Outside, a pressure bandage is fixed on the lip for several hours.

### **Algorithm for performing a flap surgery**

A flap surgery is an intervention in which access to the surgery area is created by forming a mucosal (split) or muco-periosteal (complete) flap, and at the end of the operation, the flap is placed in its former place (simple) or transferred to a new one (advanced). A flap surgery enables to process in a quality manner the surgical field under visual control.

Surgical intervention is performed at least a week after professional hygiene. The operation is performed under local anesthesia. Parallel vertical incisions are made from the vestibular and oral surfaces from the edge of the gum to the mucosal-gingival border, then the gingival papillae are dissected and the mucosal-periosteal flaps are peeled off, the surgical wound is washed with an antiseptic solution. Under visual control, subgingival hard dental deposits, infected cement, granulation and epithelial tissues are carefully removed. The inner surfaces of the flap are de-epithelized with sharp scissors. The root surface is polished with burnishers, polishers. Special attention should be paid to the need for constant irrigation of the operating field with antiseptic solutions and

isotonic sodium chloride solution. If necessary, osteoplastic (osteoinductive) materials are introduced into bone defects.

The use of osteoinductive materials is possible only after splinting loose teeth with temporary or permanent orthopedic structures.

The flap is returned in place and fixed.

## **Algorithm of ultrasonic removal of supra-gingival and subgingival dental deposits**

### ***Contraindications to the use of the ultrasound method***

#### ***Common***

Acute infectious diseases  
Pregnancy  
Children younger than 14 years  
Eye disease (cataract)  
Pacemaker

#### ***Local***

Immature tooth enamel  
Herpes simplex in the acute stage  
Zones of hard tooth tissues destruction  
Enamel microcracks  
The presence of oral diseases in the acute stage

Dental treatment is carried out by continuous movement along the neck of each tooth, without excessive pressure, starting from the vestibular surface, then the approximal and oral surfaces are processed.

The tip of the tool should be located along and at an acute angle to the surface to be treated. The tooth surface should be treated with a break, taking into account the thermal effect of the scaler on the tooth pulp. Special attention should be paid to the areas of decalcification, caries, erosion, excessive teeth attrition, restoration edges, artificial crowns, orthodontic structures and systems and implants. It is also necessary to avoid contact of the mucous membrane with the tip of the ultrasound and sound devices because of the risk to damage it.

Dental treatment should be carried out in a certain sequence in order to avoid missing individual teeth. Ultrasonic treatment is necessarily completed by removing the remnants of dental deposits with hand tools, polishing the teeth with a special paste using polishing gums and brushes,

treating the interdental spaces with floss and strips. Coating with fluorinated preparations – if necessary.

### **Algorithm of removing supra-gingival and subgingival dental deposits (with manual tools).**

Mechanical treatment of tooth surfaces is performed with manual or ultrasonic instruments, and most often in combination with the use of these tools. As a rule, after processing with electric-powered tools (sound or ultrasound equipment), it is necessary to manually remove the remnants of dental deposits and smoothen or polish the root surface. For this purpose, manual scalers are used – straight and curved, a minimal set of zone-specific Gracey curettes of four double-sided instruments (5/6, 7/8, 11/12, 13/14).

Removal of dental deposits begins with the vestibular surface of the tooth, then they are removed from the approximal surfaces and, last of all, from the oral surface.

#### ***Curette 5/6***

##### ***Vestibular surface of frontal teeth***

Treatment of the posterior-buccal surface: the patient is in a semirecumbent position, the head is turned to the right. The doctor is at “9 o’clock” position. The working hand rests on the thumb of the left hand, which holds the tooth. Direct visibility of the working area.

One cutting edge of the instrument processes the posterior – buccal surface of the tooth, and the other (on the reverse side) – the posterior-buccal surface of the tooth.

##### ***Palatal surface of frontal teeth***

Treatment of the posterior-palatine surface: the patient’s head is turned to the right and back. The doctor is at “11 o’clock” position. The working hand rests on the tooth in front (for example, when processing the posterior-palatine surface of the tooth 2.2 – the working hand rests directly on the tooth 2.1). Indirect visibility – using a mirror.

***The anterior-palatine and posterior-palatine surfaces*** are treated with different ends of the curette.

### ***Curette 11/12***

#### ***Mesial surface of masticatory teeth***

Treatment of the mesial surface (access from the buccal side): the patient's head is slightly tilted to the right. The doctor is at "10 o'clock" position. Direct support on the adjacent tooth. Direct visibility. The ring finger creates a fulcrum of the working hand, being located as close as possible to the mesial surface of the treated tooth.

Curettage of the subgingival surface is carried out by rotational movements of the forearm around the fulcrum.

Curette 11/12 is used from the buccal side to clean the mesial surface, including the entrance to the furcation.

Treatment of the mesial surface (access from the palatine side): the patient's head is inclined back and to the left. The doctor is at "8 o'clock" position. Support on the lower jaw or on the opposing teeth. Conducting along the thumb of the left hand. Direct visibility. Part of the furcation can be processed only from the palatal access. The thumb of the left hand guides and stabilizes the instrument. In order to clean the root, a very mild effort is enough, if the tool is properly sharpened.

### ***Curette 13/14***

#### ***Distal surface of masticatory teeth***

Treatment of the mesial surface (access from the buccal side): the patient's head is slightly inclined to the right. The doctor is at "10 o'clock" position. Support on the adjacent tooth.

Visibility is direct; the soft tissues of the cheek are pushed away by the mirror. The ring finger rests on the tooth 2.5, near the treated area (the distal surface of the tooth).

The part of the tool arm closest to the working part should be parallel to the tooth surface.

Treatment of the mesial surface (access from the palatine side): the patient's head is slightly inclined to the left. The doctor is at "9 o'clock" position. Support on the dorslim surface of the left hand index finger . This finger also directs the instrument and exerts pressure on it. Direct visibility. The palatine root is cleared in the direction from the palate to the contact point and furcation.

### ***Curette 7/8***

### **Mesial surface of masticatory teeth**

Treatment of the buccal surface of the tooth: the patient's head is slightly tilted in the direction of the doctor. The doctor is at "10 o'clock" position. Support on the adjacent tooth. Direct visibility. The vestibular surface is cleaned not only by vertical, but also by diagonal and horizontal movements. The middle finger is located in the first recess of the instrument's shoulder (Fig. 86). The depression on the vestibular surface corresponds to the entrance to the buccal furcation. If the roots are exposed, then near the furcation they are treated with curettes 11/12 (from the mesial side) and 13/14 (from the distal side)

### ***Palatal surface of masticatory teeth***

Treatment of the palatine surface: the patient's head is turned to the left, "outside the doctor".

The doctor is at "8 o'clock" position. Support on the occlusal surface. The fulcrum is located directly on the masticatory surface. Visibility is direct. On the palatine side, the root is usually convex, but there may be narrow grooves that make processing difficult.

Smoothness of the teeth surfaces after the procedure is checked with an explorer probe and floss in the interdental spaces.

Quality control of the manipulations performed. After removing dental deposits, the doctor should check the quality of the measures carried out with the help of a probe, a mirror, flosses, as well as with the help of occlusal peri-apical X-ray.

Each treated tooth is viewed consistently and accurately from all surfaces.

### **Algorithm for conducting non-surgical debridement**

Curettage of the parodontal pocket is a surgical manipulation aimed at reducing the depth of the parodontal pocket or eliminating it.

The purpose of curettage is to remove subgingival tartar, granulations, vegetative epithelium of the gingival crevice, inflamed connective tissue of the pocket wall.

### ***Non-surgical debridement technique.***

After medical treatment under infiltration or conduction anesthesia, subgingival dental deposits and pathologically altered root cement are extracted in the following sequence: first vestibularly, then approximately

and orally. At this, the tool is directed from the root top to the tooth crown, tightly pressing it to the surface of the root, or from the depth around the root to the edge of the crown, diagonally. In the process, the operating field is washed with an antiseptic solution. Next, removal of granulation tissue from the bottom of the pocket with an acute curette takes place. The last stage is the de-epithelization of the pocket with scissors.

After that, the surgical field is treated with an isotonic solution of sodium chloride, the gum is pressed tightly against the tooth and a protective bandage is applied.

***Postoperative care during the week:***

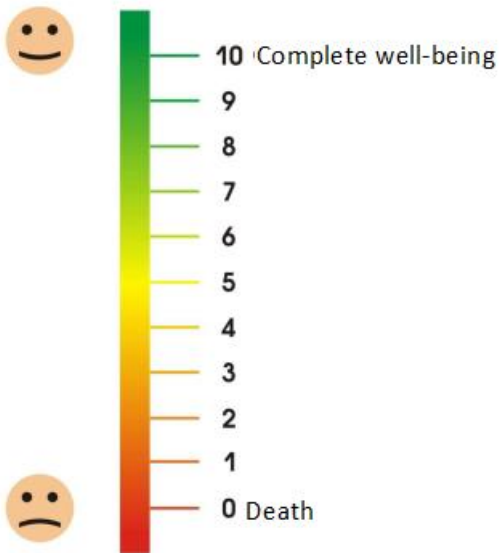
1. keep the periodontal bandage for 2 to 5 days, limiting brushing the teeth in this area; after removing the bandage, it is necessary to return to using a toothbrush.
2. medical treatment: oral baths with an antiseptic solution 2 times a day for 3-5 minutes.
3. local application of keratoplastic preparations after removal of the bandage.

PATIENT QUESTIONNAIRE

FULL NAME \_\_\_\_\_ DATE OF FILLING  
IN

HOW DO YOU ASSESS YOUR OVERALL HEALTH  
TODAY?

Please mark the value corresponding to your state of health on the  
scale.



**The algorithm and features of temporary splinting in parodontal diseases.**

A temporary splint is an orthopedic structure used to immobilize a group of teeth or the entire dentition temporarily for the treatment of parodontal diseases before a permanent splinting.

In generalized periodontitis, all teeth are included into the splint, in localized periodontitis, in addition to the affected area, teeth with an unaffected parodontium are by all means included in the splint. In bone atrophy up to\_\_\_. root length – splinting is carried out in the horizontal plane, in atrophy up to\_\_\_. – it is necessary to splint the teeth in the horizontal and vertical plane.

A temporary splint must meet the following requirements: to fix a group of teeth and/or the entire dentition, to be easy to apply and remove if necessary, to distribute pressure evenly, if necessary, to fill in an edentulous space, not to injure the oral mucosa, not to interfere with therapeutic measures, to differ by its ease to manufacture.

A temporary splint can be made of plastic, an orthodontic wire, reinforced composite based on an organic or inorganic matrix.

When planning the use of a temporary splint, attention should be paid to the severity of the disease, the presence of edentulous spaces, a decrease in the height of the lower part of the face.

After diagnostic tests and the choice of a temporary splint design, treatment is started at the same visit.

**Algorithm and features of manufacturing a temporary plastic splint**

The first stage in manufacturing a temporary plastic splint is to obtain impressions from both jaws using standard mouth spoons and alginate impression masses. It is recommended to cant the edges of the spoons with a narrow strip of adhesive plaster before removing the impressions or use a special glue for better retention of the impression material. After removing the spoons from the mouth, the quality of the impressions is checked. Models are cast from gypsum.

*Next visit.*

Determining the central ratio of the jaws to find a correct position of the lower jaw in relation to the upper one in three planes (vertical, sagittal and transversal).

Determination of the centric ratio of the jaws is carried out using wax bases made in the dental laboratory with occlusal rims. Special attention should be paid to the height of the lower part of the face. If there are edentulous spaces in the dentition, choosing artificial teeth is made.

*Next visit.*

Before applying and fitting the finished temporary splint in the mouth, it is necessary to evaluate the quality of the splint.

The splint is introduced into the mouth, its fit and fixation to the teeth are checked as well as absence of balancing.

Special attention should be paid to occlusal contacts and the absence of blocking movements of the lower jaw.

If necessary, a partial and/or complete relocation of the temporary splint is carried out with the help of auto-polymer resin.

Algorithm and features of manufacturing an oral multi-section splint made of plastic.

The first stage of manufacturing an oral multi-section splint made of plastic is to obtain impressions from one and/or both jaws using standard mouth spoons and alginate impression masses. It is recommended to cant the edges of the spoons with a narrow strip of adhesive plaster before removing the impressions or use a special glue for better retention of the impression material. After removing the spoons from the mouth, the quality of the impressions is checked. Models are cast from gypsum.

On a plaster model, an auto-polymer resin is applied in a uniform layer 2-3 mm thick on the oral side at the border from the cutting edge and/or the transition of the chewing surface to the oral one to the tooth contour height line. In the presence of tremas and edentulous spaces, they are also filled with plastic. After the plastic has cured, the oral surface is treated and polished. The splint is removed from the model and fitted in the mouth.

Special attention should be paid to the fit of the splint and its fixation to the teeth, lack of balancing.

If necessary, a partial and/or complete relocation of the temporary splint is carried out with the help of auto-polymer resin.

Fixation of an oral multi-section splint to the teeth can be carried out on various materials (dental cement, light-curing material, etc.).

Algorithm and features of manufacturing a splint from a reinforced composite based on an organic matrix.

Working with reinforcing materials based on an organic matrix requires working in special gloves and with scissors, special storage conditions. Splint manufacturing is carried out in one visit. In dental mobility of 1-2 degrees, it is not necessary to create retention points, it is located on the palatine or lingual surfaces. In dental mobility of 2-3 degrees and in splinting the lateral group of teeth, it is necessary to create retention grooves 1-1.5 mm deep, on the teeth of the anterior group, the splint can be located along the cutting edge, on the teeth of the lateral group, retention grooves are created on the occlusal surface.

***Manufacturing algorithm:***

1. Removal of dental deposits, if necessary, creation of retention points.
2. Measuring the length of the reinforcing fiber using a foil.
3. Impregnation of the fiber with a special bond to prevent separation of fibres.
4. Etching the hard tooth tissues.
5. Application and polymerization of the bonding system on the tooth tissue.
6. Applying a liquid-flowing composite and immersing a reinforcing fiber in it, modeling and polymerization.
7. Splint processing, adjustment of occlusal contacts, polishing.

***Algorithm and features of manufacturing a splint from a reinforced composite based on an inorganic matrix.***

Splint manufacturing is carried out in one visit. In dental mobility of 1-2 degrees, it is not necessary to create retention points, it is located on the palatine or lingual surfaces. In dental mobility of 2-3 degrees and in splinting the lateral group of teeth, it is necessary to create retention grooves 1-1.5 mm deep, on the teeth of the anterior group, the splint can be located along the cutting edge, on the teeth of the lateral group, retention grooves are created on the occlusal surface.

Manufacturing sequence:

1. Removal of dental deposits, if necessary, creation of retention points.
2. Measuring the length of the reinforcing fiber using a foil.
3. Impregnation of the fiber with a special bond to prevent separation of fibres.
4. Etching the hard tooth tissues.
5. Application and polymerization of the bonding system on the tooth tissue.
6. Applying a liquid-flowing composite and immersing a reinforcing fiber in it, modeling and polymerization.
7. Splint processing, adjustment of occlusal contacts, polishing.

### **Algorithm of selective grinding of hard dental tissues**

Selective grinding involves the correction of occlusion and articulation through elimination of tooth interference.

**Indications** for selective grinding of hard dental tissues are:

- ✓ Inflammatory diseases of parodontal tissues
- ✓ Diseases of the temporomandibular joint
- ✓ Increased tone of the chewing muscles
- ✓ Deformations of occlusal surfaces as a result of inappropriate filling or prosthetics
- ✓ Absence or uneven attrition of hard tooth tissues
- ✓ Anomaly of the dental-maxillary system development.

***Contra-indications;***

There are no absolute contraindications.

Relative contraindications:

- ✓ The presence of pain syndrome in acute and exacerbations of chronic TMJ diseases.

Selective sanding is elimination of tooth interference by stripping hard tissues within the enamel.

To mark occlusal contacts, articulation paper of various thicknesses is used, starting from 200 microns and ending with 8-11 microns, wax for an occludogram. An additional method for detecting occlusive contacts can be the use of a T-scan (TekScan) device. In complex cases, in complex and extensive rehabilitation, in order to examine occlusion, it is necessary to install diagnostic models in the articulator.

It is recommended to carry out selective grinding in 4-6 visits at intervals of 7-10 days for adaptation of the parodontium and the neuromuscular system. 10-15 days after the last visit, if necessary, selective grinding of teeth of all three classes is carried out, the results are checked. Repeated visits are carried out once every 6 months for examination and possible correction of occlusion.

Selective grinding is best carried out in the first half of the day. One session should not last for more than 30-40 minutes. When analyzing the occludogram, special attention should be paid to the state of the triangular

site. In a harmonious jaw relation the impressions of the masticatory teeth group are represented by three types of multiple contacts:

- ✓ in the area of support cusps at a distance of 0.5-1 mm around their top
- ✓ in the area of central fissures;
- ✓ on the lateral slope of the cusps from the approximate sides.

Rules of functional selective polishing:

- ✓ For selective grinding, air-turbine handpieces or micromotors with mandatory water cooling are used.
- ✓ Interventions are carried out on limited areas of surface enamel structures (the principle of gentle preparation).
- ✓ The height of the cusps is completely preserved to stabilize the occlusion (palatine cusps of upper molars and premolars, buccal cusps of the lower molars and premolars).
- ✓ Restoration of the anatomical shape and flattening the tooth contour in the contour height area.
- ✓ Elimination of supracontacts by the most gentle grinding method for tooth tissues.
- ✓ When grinding in the lateral occlusions, there should be a cusp contact of the same name on the working side, on the balancing side – that having a different name or its absence.

After each visit, it is necessary to polish and treat the polished surfaces with fluoride-containing preparations. To do this, it is necessary to use brushes, polishers, polishing pastes.

Most often, the techniques of functional selective grinding according to Schuyler and D. Jenkelson (1972) are used, which are the most biologically appropriate for tooth tissues. Jenkelson technique helps to establish occlusal relations in the most physiological form for the supporting tissues and convenient for the patient.

According to this technique, premature contacts identified in the central and distal occlusions are eliminated;

lateral and anterior articulatory movements of the lower jaw are not corrected at the same time. According to Schuyler method, contacts in the central and distal occlusions are first eliminated, then in the anterior occlusion and last of all in the lateral occlusions.

Teeth joining is carried out by the patient himself (without the help of a doctor) in the most comfortable sitting position for him. In the

process of functional selective grinding, the optimal occlusal relationships of the dentition at the time of their joining are completely controlled by the patient himself (a sense of comfort) and depend on individual neuromuscular control of central occlusion.

Classification of supracontacts according to Jenkelson:

- Class I – vestibular surfaces of buccal cusps of lower molars and premolars, vestibular surfaces of lower incisors and canines;
- Class II – palatine surface surfaces of palatine cusps of upper molars and premolars;
- Class III – buccal surfaces of palatine cusps of upper molars and premolars.

**Algorithm of functional selective grinding:**

***First visit***

eliminate premature contacts of class III in the distal occlusion.

***Second visit***

premature contacts of class I in the central occlusion are eliminated.

Checking and

correction of the results obtained in the previous stage.

***Third visit***

elimination of class II premature contacts in the central occlusion.

Checking and

correction of the results obtained in the previous stage.

***Fourth visit***

elimination of class III premature contacts in the central occlusion.

Checking-up

and correction of the results obtained in the previous stage.

***Fifth visit***

Control visit, check of all classes of contacts.

This technique is based on the principle of stage-by-stage approach and includes five patient visits with regularity of 5 to 10-12 days. If necessary, the time between visits can be shortened (from 3 to 7 days), but it is not recommended to change the sequence of interventions. An experienced dentist can perform selective grinding in one visit, and an additional correction can be carried out after 3 days, when the patient himself will be able to point out the areas that cause him inconvenience.



**Algorithm for filling in the odontoparodontogram according to V. Yu. Kurlandsky.**

A visual picture of the dentition state in the supporting apparatus of the preserved teeth, opposing relations of the dental arches, the functional state of the dento-facial system and the course of the process (when comparing dynamic records) is given by an odontoparodontogram according to V. Yu. Kurlandsky, which is obtained by entering the information about each tooth and its supporting apparatus in a special drawing-table.

The odontoparodontogram makes it possible to evaluate the power capabilities of the tooth attachment apparatus in order to use them for certain prosthesis designs. The odontoparodontogram is based on the data of the maximum endurance of the parodontium to the load, obtained by Haber (1939) by gnathodynamometry method. The author took the minimum endurance value equal to 24 kg and inherent in the lower and second upper incisors as 1, thus, the molars, whose endurance was 72 kg, were given the coefficient 3, the remaining teeth received intermediate coefficient values. According to V. Yu. Kurlandsky, normally, with the usual function, the attachment apparatus of each tooth in particular and the entire dental-facial system as a whole function at 50% of their capacity, and 50% remains in reserve. In atrophy of the bone tissue in the tooth socket by ...25% remains in the reserve, i.e. the parodontium's condition is compensated. In atrophy of the bone tissue in the tooth socket by ...there is no reserve left, i.e. the parodontium's condition is subcompensated. In atrophy of the bone tissue in the tooth socket by ... and more, the parodontium's condition is decompensated. All the data revealed on the basis of filling in and analyzing the odontoparodontogram are one of the fundamental factors when choosing the design of dentures – both fixed and removable. A correctly filled odontoparodontogram according to V. Yu. Kurlandsky gives the dentist the opportunity to record the status of the dento-facial system at the time of the examination in the medical history and track its dynamics.

When choosing a method for orthopedic treatment, a very important point is leveling the power relationships between opposing teeth, groups of teeth or dentitions when biting and chewing food. Otherwise,

the function of the factor that forms the dental system turns into a factor that destroys it. An odontoparodontogram is a table in which the values of the parodontium are entered in normal condition, in atrophy by .,.,. and more than the height of the tooth alveolus. To fill in the table, it is necessary to probe the depth of the parodontal pocket from the medial, distal, vestibular and oral surfaces. The maximum value is selected and is correlated with the crown part of the tooth. According to anatomical studies, the ratio of the crown part to the root is 1:2, that is why, immersion of a parodontal probe by the value of the crown part corresponds to . the height of the tooth alveolus, by half of the crown part - . alveolar heights and so on. The probing findings are entered in the corresponding column.

## ***LIST OF REFERENCE LITERATURE***

---

1. The Ministry of Health and Social Development of the Russian Federation: <http://www.minzdravsoc.ru>
2. The official website of the Russian Dental Association – e-Stomatology.ru
3. [www.mkbs10.ru](http://www.mkbs10.ru) –international classification of dental diseases ICD-C-3 based on ICD-10
4. ICD-10, International Statistical Classification of Diseases and Health-related problems, in 3 volumes-Moscow, 2003. -2440 p.
5. <http://www.who.int/classifications/icd/ICDRevision/en/>
6. Protocol for the management of patients “Dental caries”. – M.: Medical book, 2011 -76 p.
7. Protocol for the management of patients “Diseases of periapical tissues”. – M.: Medical book, 2011-116 p.
8. Protocol for the management of patients “Diseases of the tooth pulp”. – M.: Medical book, 2011-104 p.
9. Protocol of patient management. Partial absence of teeth (partial secondary adentia). Complete absence of teeth (complete secondary adentia). – Moscow: Medical book, 2011-136 p.
10. Protocol for the management of patients “Gingivitis”. Protocol for the management of patients “Vincent’s acute necrotic ulcerative gingivitis”. – M.: Medical book, 2012-96 p.
11. The nomenclature of works and services in healthcare. Approved by the Ministry of Health and Social Development of Russia on 12.07.2004-Moscow, 2004. – 211 p.; working updated version 2007 – - 198 p.
12. Abolmasov N. N. Selective grinding of teeth. – Smolensk, 2004. – 80 p.

13. Barer G. M. Therapeutic dentistry: textbook: in 3 parts – Moscow: GEOTAR-Media, 2009. – Part 2. – Periodontal diseases. – 224 p.: 236 ill.
14. Borovsky E. V. Therapeutic dentistry under the editorship. – M., 2003
15. Bezrukova I. V., Grudyanov A. I. Aggressive forms of parodontitis. – M.: MIA Publ.– 126 p.
16. Bezrukova A. P. Parodontology. – M., 1999 – - 332 p.
17. Botticelli A. T. Guide to dental hygiene. – Publishing house “Azbuka”, 2006. – 216 p., ill.
18. Wolf G. F., Rateyzhak E. M., Rateyzhak K. Periodontology; Trans. from German; Ed. Prof. G. M. Barera. – M.: MEDpress-inform, 2008. -548 p.: ill.
19. Grudyanov A. I. Periodontal diseases. – M.: Publishing house “Medical Information Agency”, 2009 – - 336 p.: ill.
20. Grudyanov A. I., Grigoryan A. S., Frolova O. A. Diagnostics in periodontology. – M., 2004. – 93 p.
21. Grudyanov A. I., Moskalev K. E. Instrumental treatment of the dental root surfaces. – M., 2005 – - 67 p.
22. Grudyanov A. I., Erokhin A. I. Surgical methods of treatment of periodontal diseases. – M., 2006. – 120 p.
23. Detjenville R. Treatment of severe periodontitis. – Publishing house “Azbuka”, 2008. – 119 p., ill.
24. Dibart S., Karima M. Practical guide to plastic periodontal surgery. – Publishing house “Azbuka”, 2007. – 110 p.
25. Dmitrieva L. A. Therapeutic dentistry. – M.: MEDpress-inform, 2003 – - 896 p.
26. Dmitrieva L. A. Therapeutic dentistry: national guidelines / edited by L. A. Dmitrieva, Yu. M. Maksimovsky. – Moscow: GEOTAR-Media, 2009 – - 912 p.

27. Dmitrieva L. A. National guidelines/ ed. by Prof. L. A. Dmitrieva. – M.: GEOTAR-Media, 2013 – 712 p.
28. Dmitrieva L. A. Parodontitis. – M.: MIA, 2007 – - 504 p.
29. Ivanov V. S. Parodontal diseases. – M.: MIA, 1998 – - 295 p.
30. Kuzmina E. M. Dental hygienist. – LLC “Rido N. N.”, 2012 – - 416 p.
31. Kopeikin V. N. Orthopedic treatment of parodontal diseases. – M.: Triad-X, 2004. – 174 p.
32. Cohen E. Atlas of cosmetic and reconstructive periodontal surgery / Translated from English. edited by Prof. O. O. Yanushevich-3<sup>rd</sup> ed. – Moscow: JSC “Moscow textbooks”, 2011 – - 512 p.
33. Leontiev V. K., Maly A. Yu. Conceptual approaches to the development of protocols for the management of patients in dentistry // Problems of standardization in healthcare. – 2007. – No. 6. – pp. 5-10.
34. Nikolaev A. I. Practical therapeutic dentistry: textbook. manual/ A. I. Nikolaev, L. M. Tsepov – - 9<sup>th</sup> ed., reprint. and suppl. – M.: MEDpress-inform, 2010. – 928 p.
35. Newman M, Winkelhoff A. Antimicrobial drugs in dental practice. – Publishing house “Azbuka”, 2004. – 328 p.
36. Muller H.-P. Parodontology. Scientific ed.ed. In Russian. Prof. A. M. Polytun. Translated from German-Lvov: GalDent, 2004 – - 256 p.
37. Orekhova L. Yu. Periodontal diseases. Edited by / Moscow: Poly Media Press, 2004 – - 432 p.: fig.
38. Orekhova L. Yu. “Fundamentals of professional oral hygiene” – methodological guidelines-St. Petersburg: 2004. – 56 p.
39. Orthopedic dentistry: Textbook / Edited by V. N. Kopeikin, M. Z. Mirgazizova. – 2<sup>nd</sup> ed., supplement-M.: Medicine, 2001 – - 624 p.
40. Roulet J.-F. Professional prevention in the practice of a dentist: atlas of dentistry / Jean-Francois Roulet, Stefan Zimmer; trans. from German; under the general editorship of S. B. Ulitovsky, S. T. Pyrkov. – M.: MEDpress-inform, 2010. – 368 p.: ill.

41. Sivovol S. I. Clinical aspects of parodontology. M. – 2001. – 166 p.
42. Therapeutic dentistry: Textbook / Edited by M. Yu. Maksimovsky. – M.: Medicine, 2002 – - 640 p.
43. Tsepov L. M. Parodontal diseases: a look at the problem. – M., 2006. – 192 p.
44. Tsepov L. M., Nikolaev A. I., Mikheeva E. A. Diagnostics, treatment and prevention of parodontal diseases. – 3<sup>rd</sup> ed., corr. and add. – M.: MEDpress-inform, 2008. – 272 p.: ill.
45. Ulitovsky S. B. Practical oral hygiene. Moscow., 2002.
46. Yanushevich O. O., Dmitrieva L. A., Revazova Z. E. Parodontitis, XXI century. – Moscow: MGMSU, 2012 – - 366 p.
47. Yanushevich O. O., Grinin V. M., Pochtarenko V. A., Runova G. S., et al. Periodontal diseases. A modern view on clinical and diagnostic therapeutic aspects: textbook recommended by the Ministry of Health and Social Development of the Russian Federation and the Ministry of Education of the Russian Federation / ed. by O. O. Yanushevich. – Moscow: GEOTAR-Media, 2010. – 160 p.
48. Yanushevich O. O. Dental morbidity of the Russian population. The condition of periodontal tissues and oral mucosa. / Edited by Prof. O. O. Yanushevich-M.: MGMSU, 2008 – - 228 p.

## ***CONCLUSION***

---

The control of students' knowledge consists of checking the initial level of knowledge in related disciplines or in sections taught at the department earlier and checking the knowledge on the training subject. The questions asked at this stage are reflected in relevant sections of the training manual.

The theoretical part of the practical lesson supposes a discussion between the teacher and the audience. The teacher explains the students the theoretical justification of manual skills, implementation of which is expected in this practical lesson.

The demonstration part of the practical lesson involves the teacher showing thematic patients, placing correct emphases focused on the topic of the practical lesson. The demonstration of laboratory stages by a dental technician is aimed at supplementing clinical knowledge and skills with laboratory ones, getting acquainted with dental equipment and developing skills for its operation.

Independent students' work involves the development of manual skills necessary in further work of a dentist-orthopedist.

Generalization of the lesson is based on the analysis of mistakes made by students in the process of mastering the topic of practical training. Incomprehensible theoretical aspects, clinical and laboratory errors that have arisen and the ways to eliminate them are analyzed. At the end of the lesson, the teacher voices the next topic, places accents that are significant for studying the new material, recommends literature for independent preparation of students for a new practical lesson.

For conducting practical and laboratory classes for 5th-year students in orthopedic dentistry "Prosthetics of patients with periodontal diseases". The training manual is divided into practical classes, according to the approved work program, compiled in accordance with the Federal State Educational Standard VO 2021.

# CONTENTS

---

<b>PREFACE</b> .....	2
<b>Lesson №1.</b> Parodontium diseases. Classification. Etiology. Pathogenesis. Aims of orthopedic treatment. The main symptoms of parodontites. Determining the nosological forms of parodontium diseases — focal parodontitis (traumatic node) and generalized parodontitis.....	3
<b>Lesson №2.</b> Methods for studying the condition of the parodontium and their diagnostic significance: probing, determining the mobility of teeth, conducting the Schiller-Pisarev test, occlusiography, studying the orthopantomogram, filling in the odontoparodontogram and its analysis.....	6
<b>Lesson №3.</b> Examination of patients with parodontal diseases. Taking impressions: studying diagnostic models, detecting premature contacts. Treatment plan. The basics of choosing the designs of therapeutic devices.....	13
<b>Lesson №4.</b> Complex therapy of parodontites. Classification of splints. Types of dental arch stabilization. Temporary splinting.....	19
<b>Lesson №5.</b> Focal parodontitis. Etiology. Pathogenesis. Clinical presentation. Orthopedic methods of treatment for focal parodontitis. Justifying the design of the splint (or splint-prosthesis) and its length based on the examination data and analysis of odontoparodontograms. Requirements for medical devices in the treatment of focal periodontitis”.....	25

<b>Lesson №6.</b> Generalized parodontitis. Etiology. Pathogenesis. Clinical presentation. Treatment .....	33
<b>Lesson №7.</b> Indications for tooth extraction in parodontal diseases. Temporary removable plate prostheses – immediate insertion dentures. Indications for manufacturing, purpose. Fixed and removable immediate insertion prostheses. Preparation of plaster models for the manufacture of immediate insertion prostheses. The method of splinting. Subsequent stages of patients’ treatment. The importance of early prosthetics in parodontal diseases.....	40
<b>Lesson №8.</b> Imposition of complex splints and splint prostheses. Rehabilitation of patients with parodontitis the stages of orthopedic treatment. Prognosis. The role of oral hygiene in patients with the presence of dentures parodontal diseases”.....	45
<b>Lesson №9.</b> Orthopedic treatment with clasp prostheses with a system of fixation on molar denture clasps in partial adentia and parodontal diseases .....	48
<b>Lesson №10.</b> Orthopedic treatment of partial adentia with clasp prostheses with a telescopic, interference and bar fixation system.....	64
<b>Lesson №11.</b> Parallelometry (studying jaw models in a parallelometer).....	70
<b>APPENDIX</b> .....	76
<b>LIST OF REFERENCE LITERATURE</b>	201
<b>CONCLUSION</b> .....	206